



US EDITION

# Specular Microscopy Clinical Cases

CEM-530 Specular Microscope

# Contents

---

<b>Contributing Professionals .....</b>	<b>1</b>
<b>Introduction .....</b>	<b>2</b>
<b>Prof. Ekkehard Fabian Case Examples .....</b>	<b>4</b>
<b>Dr. Alaa M. ElDanasoury Case Examples .....</b>	<b>6</b>
<b>Dr. Richard Yudi Hida Case Examples .....</b>	<b>8</b>

# Contributing Professionals



## **Ekkehard Fabian, Prof. Dr. med.**

.....AugenCentrum, Rosenheim, Germany

Co-founder and medical director of the AugenCentrum Rosenheim group practice and outpatient ophthalmic surgical center

After serving as a senior physician at the Technical University of Munich, University Eye Clinic (1984-1988), Prof. Fabian became the medical director of Ophthalmic group practice, Rosenheim (1988-1998).

Prof. Fabian specializes in quality management, image guided surgery, ophthalmic devices, intraocular lenses, corneal endothelial disease, and cataract surgery.



## **Alaa M. ElDanasoury, MD, FRCSEd.**

..... Magrabi Hospitals & Centers, Jeddah, Kingdom of Saudi Arabia

Chief Medical Officer and Director of Cornea and Refractive Surgery Units of the Magrabi Hospitals & Centers

Dr. ElDanasoury currently serves as Chief Medical Officer and Director of Cornea & Refractive Surgery Units of the Magrabi Hospitals & Centers, a chain of 21 Hospitals & Centers, and the largest in the Middle East.

Dr. ElDanasoury was among the very first surgeons to perform excimer laser surgery in the world and was the first to introduce many ophthalmic procedures to the Middle East including LASIK, phakic IOLs, intracorneal ring segments, conductive keratoplasty, crosslinking, corneal inlays, premium IOLs and femtosecond cataract laser surgery.



## **Richard Yudi Hida, MD**

..... Santa Casa de Sao Paulo, Sao Paulo, Brazil

Chief of Cataract Division of the Department of Ophthalmology and Director of the Eye Bank of the Santa Casa de Sao Paulo

Dr. Hida completed his residency at the same institution and was research fellow in Keio University (2002-2003), Tokyo, Japan.

Dr. Hida also is coordinator of the Ocular Surface Study Group at Hospital das Clinicas - Universidade de Sao Paulo (HC-USP), Sao Paulo, Brazil.

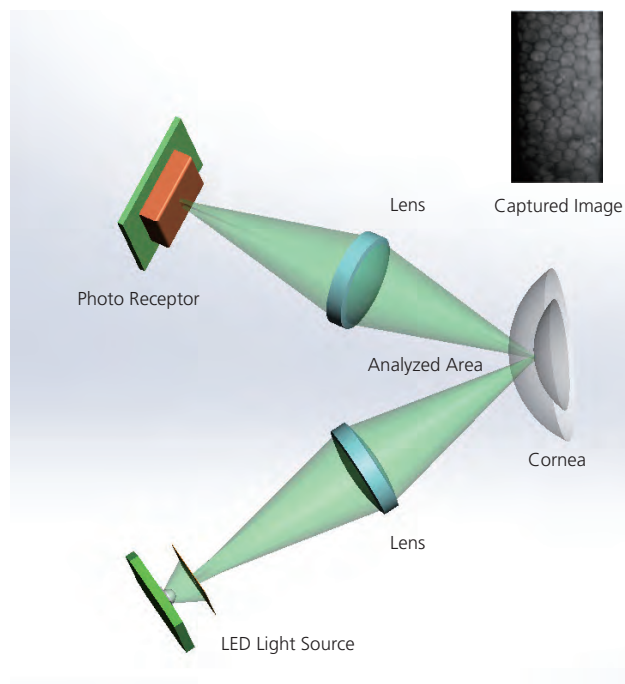
Dr. Hida specializes in cataract, cornea and refractive surgery and also has research interests in retina and eye banking.

Dr. Hida collaborated with Dr. Fábio Ursulino and Dr. João Victor Veloso Gonçalves Godinho to collect the cases.

# Introduction

## Principle of Specular Microscope

The specular microscope is a device for non-invasive imaging and analysis of the corneal endothelial layer. A variety of values can be analyzed by specular microscopy including, cell density, size and shape. The technology is based on projecting light onto the posterior surface of the cornea to capture the image that is reflected from the optical interface between the corneal endothelial layer and the aqueous humor. The image is automatically analyzed and displayed as a specular photomicrograph. In clinical practice, specular microscopy is commonly used for endothelial cell examination. It is also widely used as a screening device pre / postoperatively for cataract surgery. The endothelial layer is examined for surgical planning to avoid complications, such as postoperative corneal opacification.

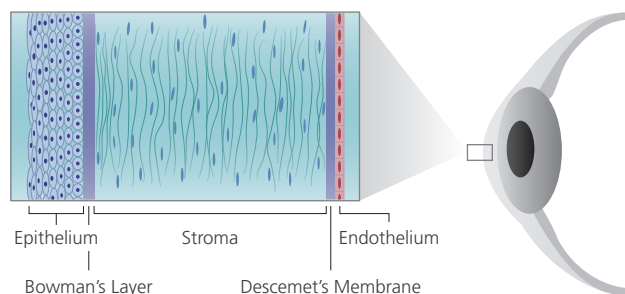


Principle of specular microscope

## Endothelium Cells

The endothelial layer is the innermost layer of the cornea and functions to maintain corneal clarity and corneal health. The normal human corneal endothelial cell is hexagonal in shape.

Endothelial cell density is constantly changing throughout life. From early childhood to approximately eighty years of life, the endothelial cell density decreases from approximately 3000-4000 cells/mm<sup>2</sup> to 2600 cells/mm<sup>2</sup>. The central endothelial cell density decreases at a rate of 0.6% annually in normal corneas.\*<sup>1</sup> Additionally, the endothelial cell density varies across populations. For adults between 20 to 40 years of age, endothelial cell density can vary from 2500 to 3800 cells/mm<sup>2</sup> based on ethnicity. An average density of 500 cell/mm<sup>2</sup> is required for the endothelial pump to function.\*<sup>2</sup>



Structure of the cornea

	Corneal Endotheliopathies
<b>Primary</b>	Fuch's Endothelial Dystrophy (Corneal Guttata) Posterior Polymorphous Dystrophy (PPD) Congenital Hereditary Endothelial Dystrophy (CHED) Iridocorneal Endothelial Syndrome (ICE)
<b>Secondary</b>	Effects of Surgical Procedures Contact Lens Wear
<b>Viral</b>	Cytomegalovirus Endothelitis Herpes Simplex Endothelitis

Types of corneal endotheliopathies classified by primary, secondary and viral causes.

Bourne, W.M.: Biology of the corneal endothelium in health and disease. Eye (2003) 17, 912-918. doi:10.1038/sj.eye.6700559

Reference:

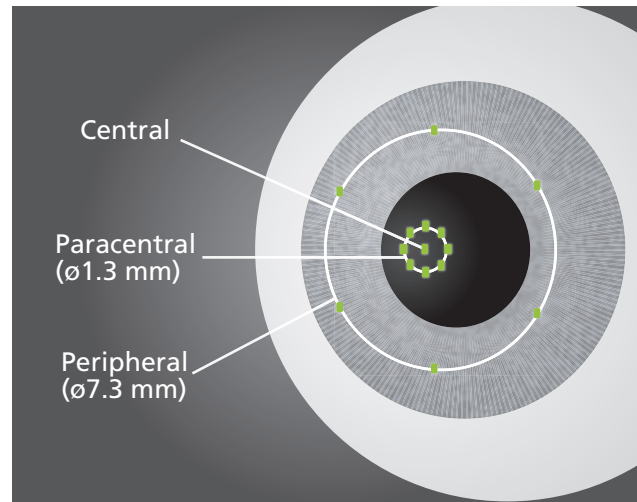
\*<sup>1</sup> Derek W. DelMonte, MD, Terry Kim, MD. Anatomy and physiology of the cornea. J Cataract Refract Surg 2011; 37:588-598

\*<sup>2</sup> Ewete T, Ani EU, Alabi AS. Normal corneal endothelial cell density in Nigerians. Clin Ophthalmol. 2016 Mar 18;10:497-501. doi: 10.2147/OPHTH.S97070. eCollection 2016.


## CEM-530 Specular Microscope

The CEM-530 specular microscope performs conventional central and peripheral (7.3 mm diameter) specular microscopy, and is unique in incorporating paracentral imaging. Paracentral images are captured from 8 points at a 5° visual angle on a 1.3 mm diameter for an enhanced assessment surrounding the central aspect of the cornea.

The combination of central, paracentral and peripheral imaging provides an overall view that can be used for detailed morphological and quantitative evaluation of the endothelial layer and individual cells.



CEM-530 capture points



0.55 mm

0.25 mm

Image capture area of the CEM-530

Endothelial image capture Position	Central	1 point
	Paracentral	8 points (5° visual angle, 45° spacing)
	Peripheral	6 points (27° visual angle, 60° spacing)
Pachymetry Measurement range	300 to 1,000 $\mu\text{m}$	
Accuracy	$\pm 10 \mu\text{m}$	
Auto Tracking / Auto Shot	X-Y-Z directions / Available	

CEM-530 product specification

## CEM-530 Viewer for NAVIS-EX

### Data Management and Endothelial Cell Count Progression Follow-up and Comparison Paracentral Display with Peripheral Imaging

CEM Viewer software allows viewing and working with CEM-530 data within NAVIS-EX, an image filing software from NIDEK.

This software enhances the capability of the CEM-530, with additional features that increase clinical efficiency.





# Prof. Ekkehard Fabian Case Examples

## Case 1


### Endothelial Decompensation (Right), Low Endothelial Cell Density (Left)

77-year-old male

Right: Endothelial decompensation in October 2016 after complicated cataract surgery in 2010.

Very low number of cells detected (66), low CD, significant pleomorphism.

Left: Clear cornea with low endothelial cell density. Low number of detected cells (459), low hexagonality.



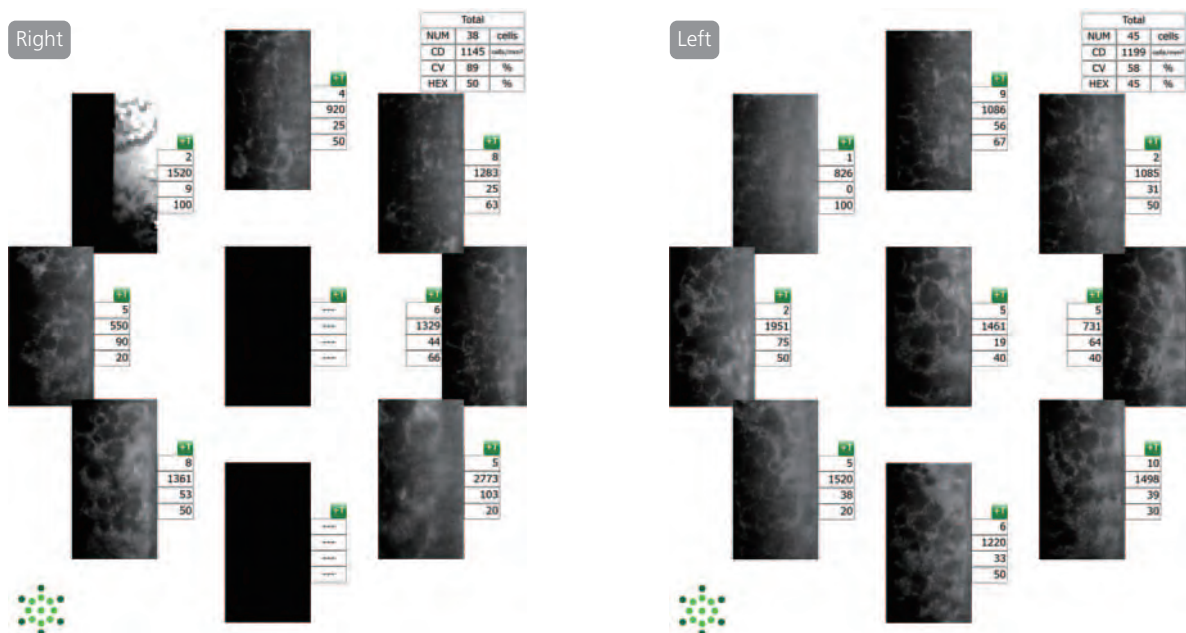
## Case 2

### Bilateral Fuch's Endothelial Corneal Dystrophy

81-year-old female

Very low CD with high variability (931 – 1951) and low detectable cells per image (2 – 10).

Polymegathism and pleomorphism.



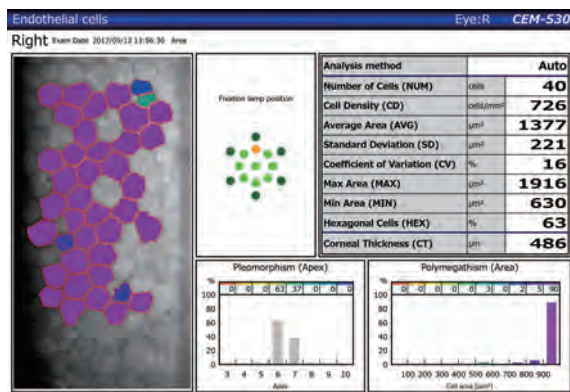
### Case 3

## Multiple Corneal Keratoplasties, Herpes Simplex Endotheliopathy


52-year-old female

Multiple corneal keratoplasties in 1992, 2004 and 2013. Low CD (755), polymegathism and pleomorphism.

Slight reduction in endothelial pump function causing a mild decrease in endothelial thickness.



CEM-530 image color coded by cell area.  
Polymegathism is visible.



### Specular Microscopy:

Since its introduction in 1981, endothelial specular microscopy (ESM) has been fundamental to assessing and aiding in the refinement of surgical procedures. The use of specular microscopy prompted the introduction of ophthalmic viscoelastic devices; resulted in changes to phacoemulsification such as the hyperpulse mode; allowed evaluation of the safety and complications of anterior chamber IOLs. These advances resulted in greater protection of endothelial / corneal tissue from surgically induced damage. New techniques of corneal perforation or lamellar corneal tissue transplantation with endothelial cells would not be possible without the knowledge of the endothelial structure from specular microscopy. ESM is mandatory to document progress in the surgical skills of ophthalmology residents. ESM is used to evaluate new technologies such as the femtosecond cataract laser to document the safety of this procedure. The decision to implant new IOLs with trifocal optics is partially based on documenting intact endothelial cells. Currently, there are numerous indications that require examination of the endothelial cells with ESM. Documentation and evaluation of endothelial cells involves the use of advanced technology and should be performed at every ophthalmic surgical center.

Evaluation with ESM includes measurement of endothelial cell density, variation in cell sizes (polymegathism), and variation in hexagonality (pleomorphism) and comparison to normal values. Hence advanced technology such as ESM will aid in preoperative evaluation, surgical planning and postoperative care.

### Paracentral Imaging:

Although advanced endothelial microscopes such as the CEM-530 are fundamental to clinical and surgical practice, there is no current method to remeasure the exact same area of endothelial cells. Hence, evaluation of as many cells as possible is recommended for greater validity and better endothelial evaluation. Evaluation of more regions of endothelial cells within one examination help increase the number of cells detected from 250 to 2500 cells, which is a quantitative advantage of paracentral imaging. Additionally, pathologies often occur in the paracentral and peripheral cornea. Hence the effect of these pathologic changes can be evaluated. Furthermore, minor changes adjacent or near the surgical entrance can be evaluated. These are qualitative advantages of paracentral imaging.

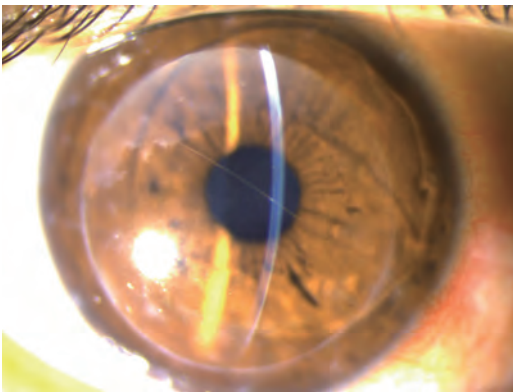
# Dr. Alaa M. ElDanasoury Case Examples

## Case 1

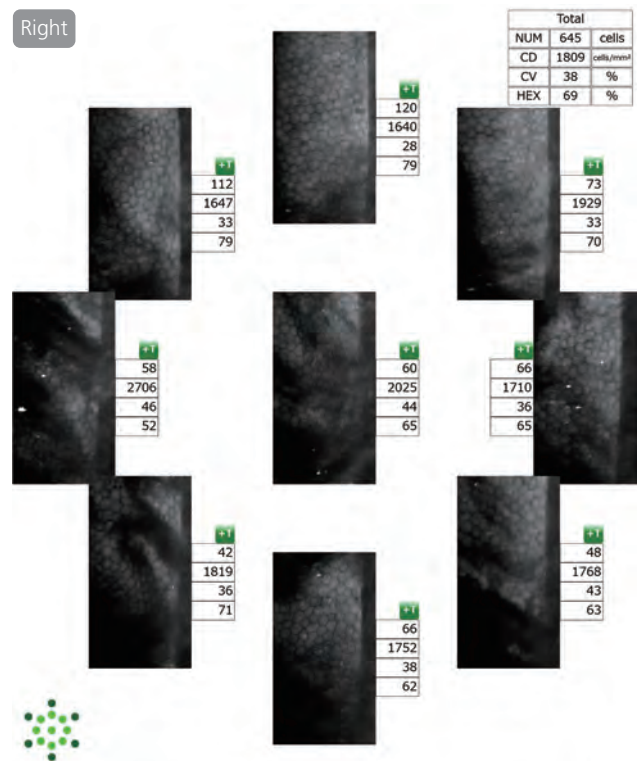
### Descemet's Fold Post-DALK

37-year-old male

Three years after DALK, the cornea is clear except for some visually insignificant scarring at the suture line. A Descemet's fold is present through the pupillary area (image). Polymegethism and pleomorphic changes are present in the mid-peripheral cornea, in the region of the Descemet's membrane fold. These folds usually do not affect visual acuity unless they are large and located centrally.



Eye image. Descemet's fold is present through the pupillary area.




## Case 2

### Paracentral and Peripheral Corneal Guttae

55-year-old female

Bilateral cataract. Routine preoperative specular microscopy shows few corneal guttae in the mid-peripheral cornea. Endothelial cell shape, cell density and coefficient of variation (CV) are within normal limits. To protect the endothelium, some precautions were taken during surgery, including the use of dispersive viscoelastic and relatively low vacuum during phacoemulsification.



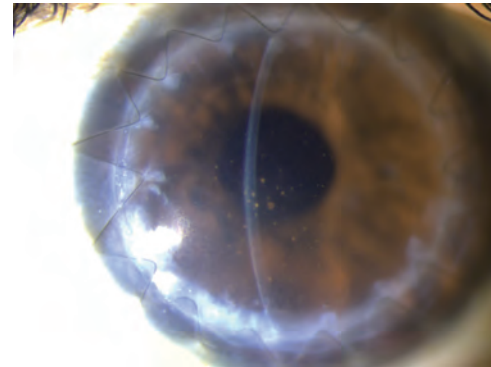
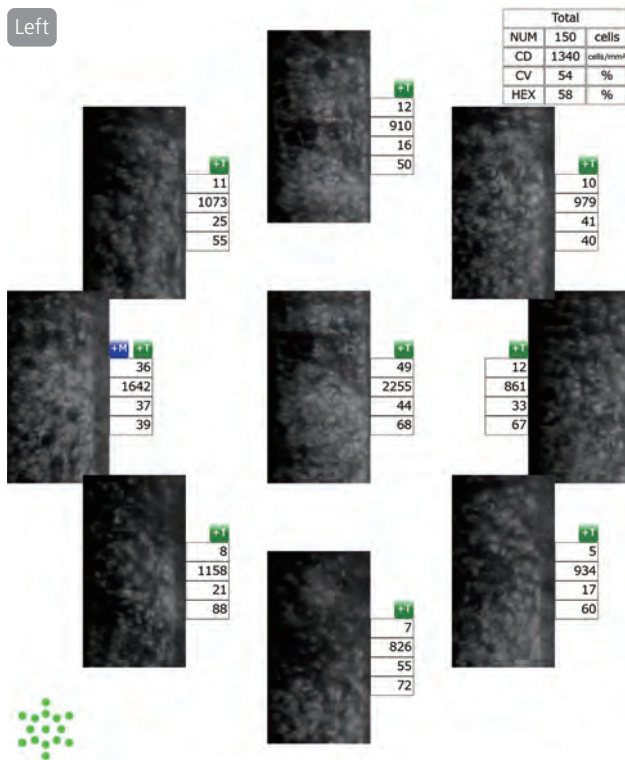


### Case 3

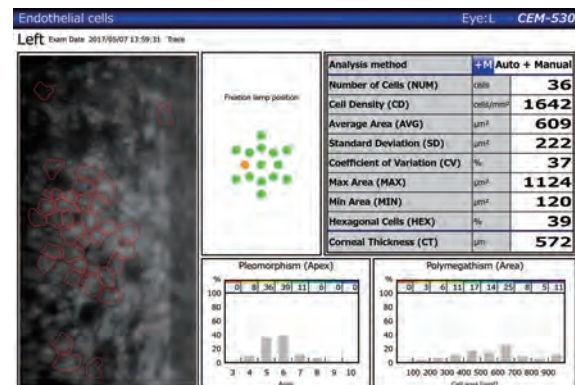
## Endothelial Rejection after Penetrating Keratoplasty (PKP)

45-years-old female

An episode of endothelial rejection occurred after PKP + ECCE + IOL. The central part of the graft appears clear and endothelial rejection is causing peripheral corneal edema. The clinical image shows peripheral edema and pigmented keratic precipitates typical of endothelial rejection.



Eye image. Peripheral corneal edema can be seen.



Combination of automatic and manual analysis.

### Specular microscopy:

Non-contact specular microscopy plays a fundamental role in daily practice for corneal and refractive surgeons. It facilitates prompt and accurate diagnosis of corneal endothelial pathologies. It is the optimal method to assess the structure and function of the corneal endothelium. Specular microscopy allows identification of underlying corneal pathology and aids in developing a treatment plan. Specular microscopy also allows long term evaluation of endothelial function in eyes with ocular pathology that may compromise the endothelium such as endothelial dystrophies, long term glaucoma, uveitis and after intraocular surgery.

### Paracentral Imaging:

Assessing the central endothelial structure is important in routine examination; however, a more detailed examination of the endothelium entails studying the paracentral and mid-peripheral endothelium. Pathology is more evident peripherally in conditions where the paracentral and peripheral endothelium are more prone to stress such as, eyes with anterior chamber phakic lenses, eyes with glaucoma shunts and in cases of posterior polymorphous dystrophies. Additionally, inclusion of the paracentral and mid-peripheral regions increases the population of cells analyzed, allowing greater statistical power for assessing the overall status of the corneal endothelium.

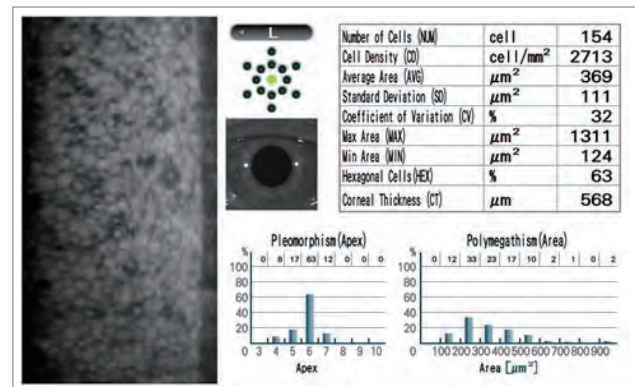
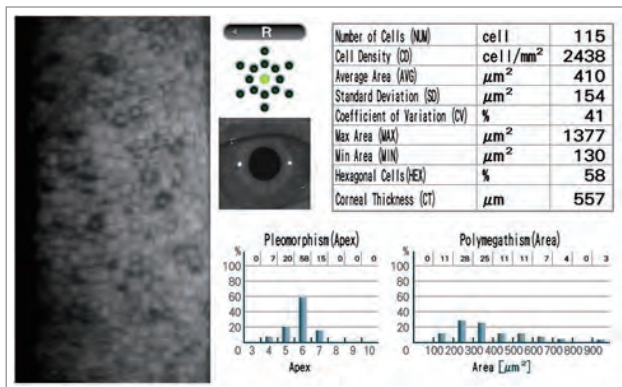
# Dr. Richard Yudi Hida Case Examples

## Case 1

### Initial Herpetic Endothelitis

24-year-old male

This patient's right eye shows normal endothelial density for his age. However, there is an increased coefficient of variation and several dark areas suggesting swelling / edema of one or more endothelial cells due to inflammation.

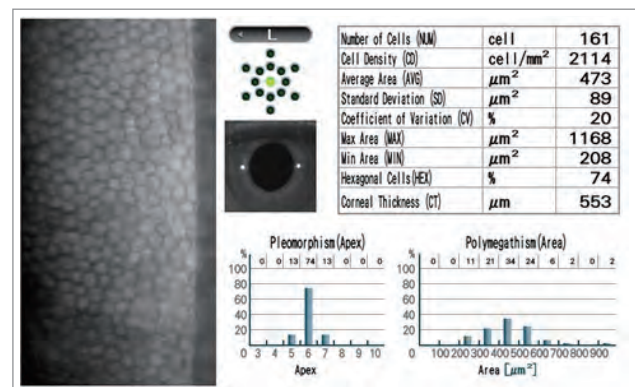
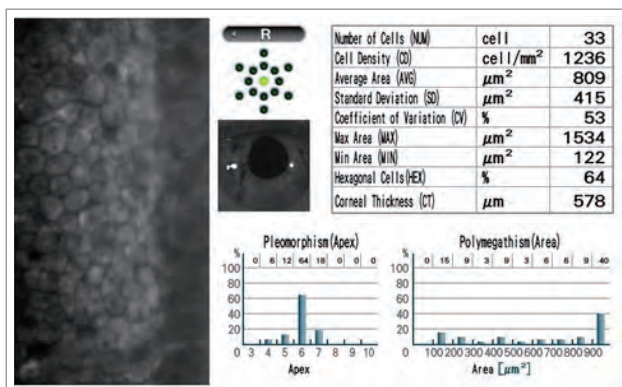


## Case 2

### Iridocorneal Endothelium Syndrome (ICE syndrome) - Variant: Chandler Syndrome

30-year-old female

This patient's right cornea showed significant difference in endothelial density when compared to the left cornea with polymegathism (increase in cell size), pleomorphism (change in shape) and some dark areas suggesting swelling / edema of endothelial cells.

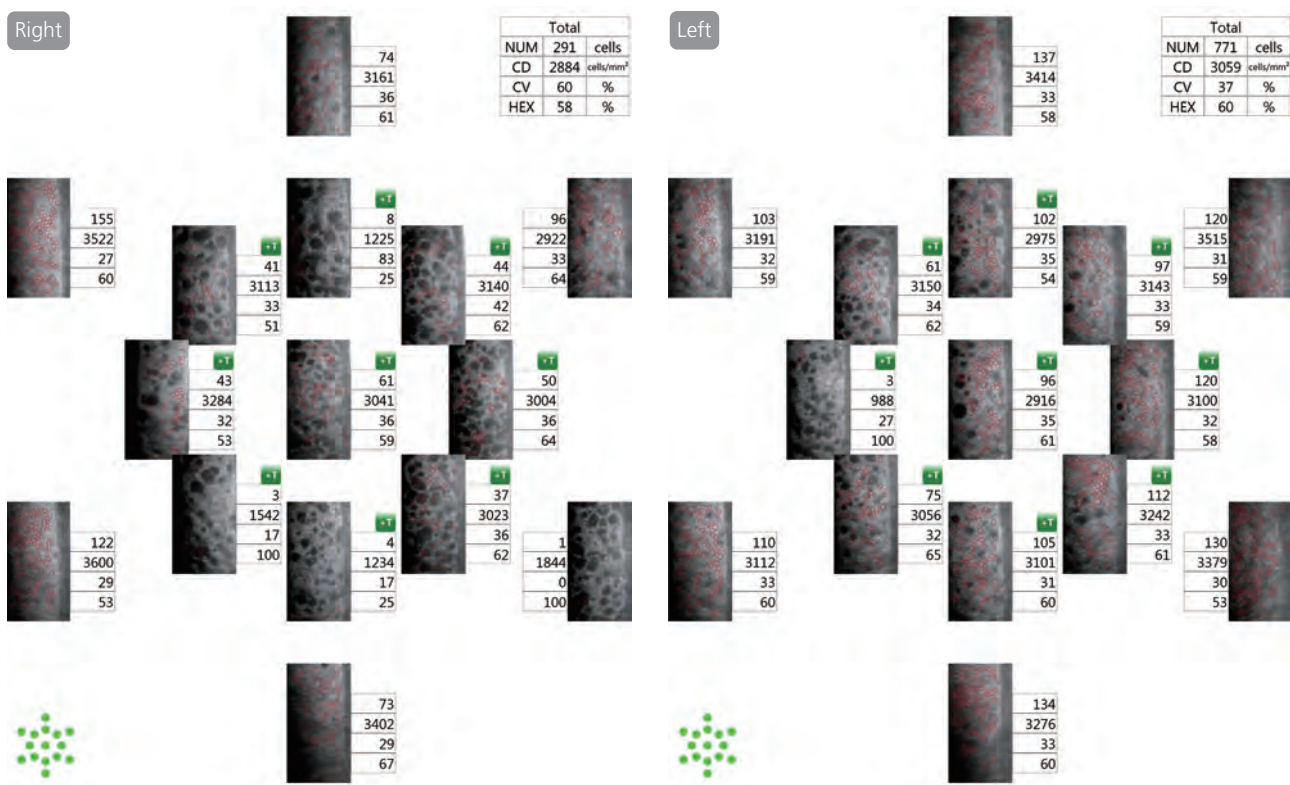


### Case 3

#### Fuch's Dystrophy

37-year-old female

Slit lamp biomicroscopy indicates abnormal endothelial cells. This observation was confirmed with non-contact specular microscopy. In this case the central and paracentral endothelium are more compromised, with greater guttae, compared to the peripheral endothelium which is expected due to the natural progression of this disease. However, the cornea was transparent and the patient had no visual complaints.



#### Specular microscopy:

Corneal specular microscopy is important for clinical and surgical follow-up of the endothelial cell pattern and status. For example, specular microscopy allows the evaluation of transient and chronic changes in endothelial cell morphology in contact lens users and it can be used for surgical planning and to assess donor corneas. However, studies have indicated some general limitations of specular microscopy. The limitations include differences in image quality, area of analysis, calibration, and number of marked and analyzed cells that constitute potential sources of inconsistency, bias,


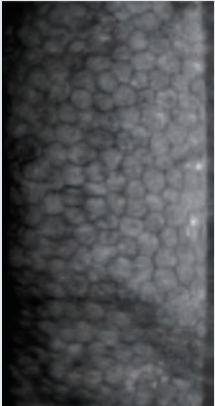
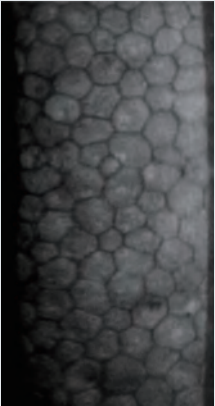
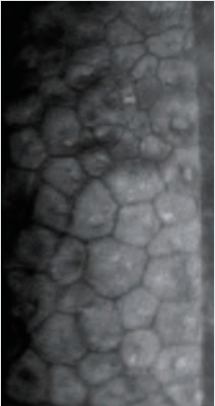
limited reproducibility, reliability and validity. Multiple images of different areas of the cornea, manual evaluation of abnormal endothelial patterns and counting as many cells as possible using NAVIS-EX software can minimize these limitations.

#### Paracentral imaging:

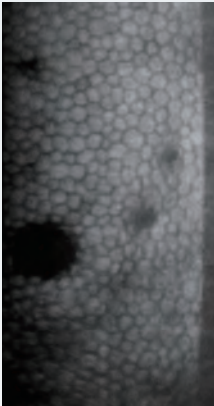
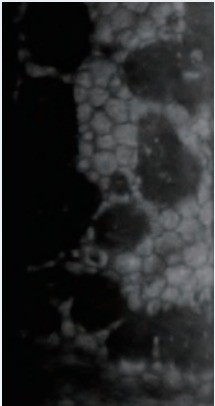
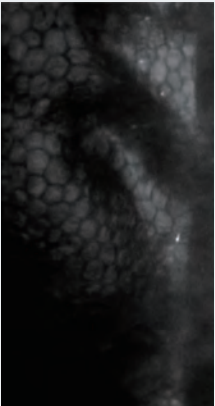

The CEM-530 by NIDEK allows analysis of different corneal regions and, thus, access to a larger endothelial sample per cornea. Counting as many cells as possible per captured image (150 cells or more) is possibly the most reliable information for endothelial health in normal or diseased corneas.



### Difference by Cell Density

2000~ (cell/mm <sup>2</sup> )	1000~2000 (cell/mm <sup>2</sup> )	500~1000 (cell/mm <sup>2</sup> )	~500 (cell/mm <sup>2</sup> )
			

### Difference by Pathology

Guttata	Fuch's Dystrophy	Descemet's Fold Post-DALK	Polymegathism
			

Images courtesy of: Prof. Ekkehard Fabian  
Dr. Alaa M. ElDanasoury  
Dr. Richard Yudi Hida

Caution: U.S. Federal Law restricts this device to sale, distribution, and use by or on the order of a physician or other licensed eye care practitioner.  
Specifications may vary depending on circumstances in each country.  
Specifications and design are subject to change without notice.  
All brand and product names are trademarks or registered trademarks of their respective companies.



HEAD OFFICE  
(International Div.)  
34-14 Maehama, Hiroishi  
Gamagori, Aichi 443-0038,  
JAPAN  
TEL: +81-533-67-8895  
URL: <http://www.nidek.com>

TOKYO OFFICE  
(International Div.)  
3F Sumitomo Fudosan Hongo  
Bldg., 3-22-5 Hongo, Bunkyo-ku,  
Tokyo 113-0033, JAPAN  
TEL: +81-3-5844-2641  
URL: <http://www.nidek.com>

NIDEK INC.  
47651 Westinghouse Drive,  
Fremont, CA 94539, U.S.A.  
TEL: +1-510-226-5700  
+1-800-223-9044  
(US only)  
URL: <http://usa.nidek.com>

NIDEK S.A.  
Europarc,  
13 rue Auguste Perret,  
94042 Créteil, FRANCE  
TEL: +33-1-49 80 97 97  
URL: <http://www.nidek.fr>

NIDEK TECHNOLOGIES S.R.L.  
Via dell'Artigianato,  
6/A, 35020 Albignasego (Padova),  
ITALY  
TEL: +39 049 8629200/8626399  
URL: <http://www.nidektechnologies.it>

NIDEK (SHANGHAI) CO., LTD.  
Rm3205, Shanghai Multi Media  
Park, No.1027 Chang Ning Rd,  
Chang Ning District, Shanghai,  
CHINA 200050,  
TEL: +86 021-5212-7942  
URL: <http://www.nidek-china.cn>

NIDEK SINGAPORE PTE. LTD.  
51 Changi Business Park Central  
2, #06-14, The Signature  
486066, SINGAPORE  
TEL: +65 6588 0389

[Manufacturer]