



U.S. Edition

# Integrated Multimodal Retinal Imaging Atlas Mirante

Giovanni Staurenghi, MD  
Srinivas R. Sadda, MD  
Mariano Cozzi, MSc  
Giulia Corradetti, MD

# Contents

Page

Mirante outline / Retro mode	5
Case 1: Choroidal Neovascularization (CNV)	6
Case 2: Bilateral Geographic Atrophy (GA) Secondary to Age-related Macular Degeneration (AMD)	8
Case 3: Choroidal Neovascularization Associated with Age-related Macular Degeneration (AMD) with Central Serous Chorioretinopathy (CSCR)	10
Case 4: Reticular Pseudodrusen for Age-related Macular Degeneration (AMD)	12
Case 5: Retinal Arterial Macroaneurysm (RAM)	14
Case 6: Retinal Angiomatous Proliferation (RAP)	16
Case 7: Branch Retinal Vein Occlusion (BRVO)	18
Case 8: Stargardt Disease Related to Mutations in the ABCA4 Gene	20
Case 9: Bilateral Rhegmatogenous Retinal Detachment in a High Myope	22
Case 10: Hydroxychloroquine Retinopathy	24
Case 11: Best Vitelliform Macular Dystrophy	26

## Authors



**Giovanni Staurenghi, MD**, is a Professor of Ophthalmology and the Chairman of the University Eye Clinic and Director of the University Eye Clinic Department of Biomedical and Clinical Science “Luigi Sacco” at the Luigi Sacco Hospital in Milan, Italy. His research, publications, and lectures have an important bearing on retinal degeneration; his work is focused on different types of imaging and treatment.



**SriniVas R. Sadda, MD**, is the President and Chief Scientific Officer of the Doheny Eye Institute, the Stephen J. Ryan – Arnold and Mabel Beckman Endowed Chair, and Professor of Ophthalmology at the University of California – Los Angeles (UCLA) Geffen School of Medicine. His major research interests include automated retinal image analysis, retinal substructure assessment, and advanced retinal imaging technologies.



**Mariano Cozzi, MSc**, is an Orthoptist and Imaging Specialist at the Eye Clinic, Department of Biomedical and Clinical Science “Luigi Sacco”, University of Milan. His main area of research is multimodal imaging and OCT interpretation.

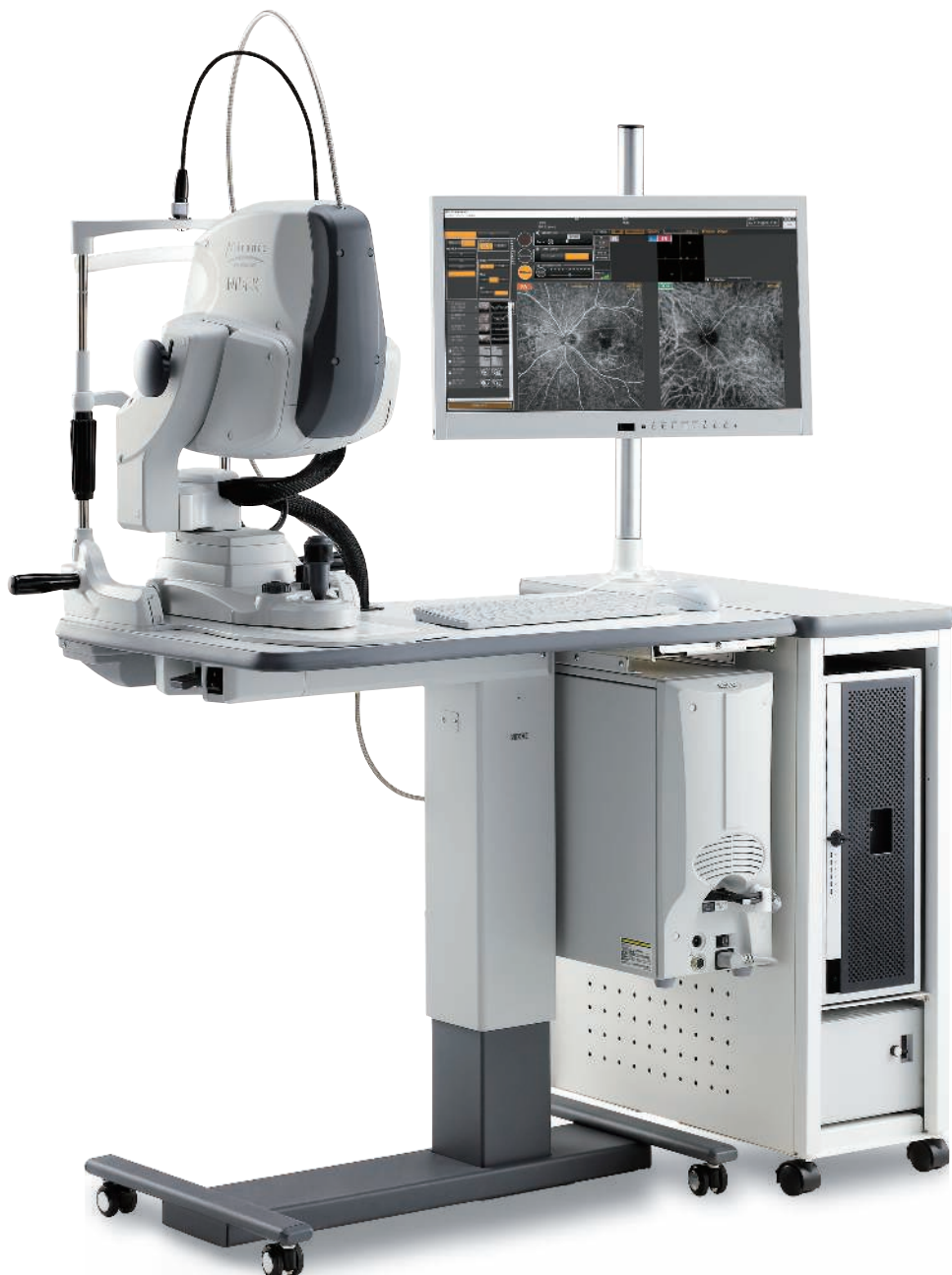

**Giulia Corradetti, MD**, is a Clinical and Research Fellow at Doheny Eye Institute, affiliated UCLA in Los Angeles, CA. Her main area of research is medical retina and retina imaging.



## The Ultimate Multimodal Imaging Platform State-of-the-art SLO/OCT Combo

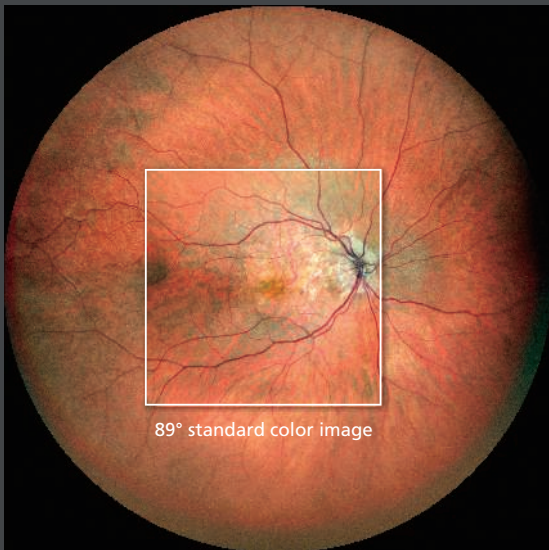
A powerful diagnostic platform that generates even greater detail when imaging the retina allowing for a comprehensive assessment of the most challenging cases of pathology



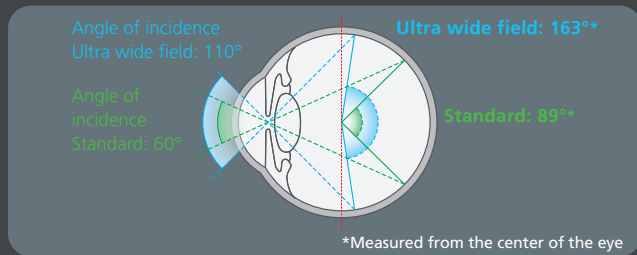


# Mirante outline Color / IR / Retro mode / FAF / FA / ICG / OCT

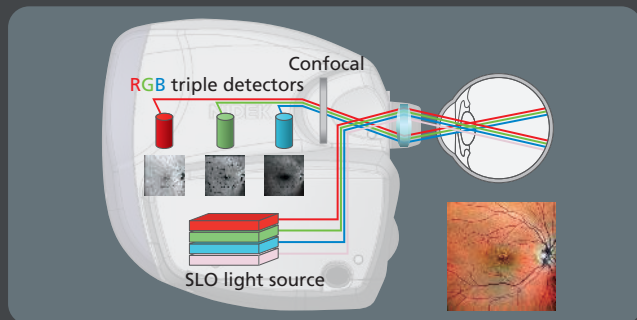
The Mirante is an innovative combined SLO/OCT, multimodal imaging device for non-invasive, seamless imaging of the fundus and anterior segment.



163° ultra wide field color image



Angle of view

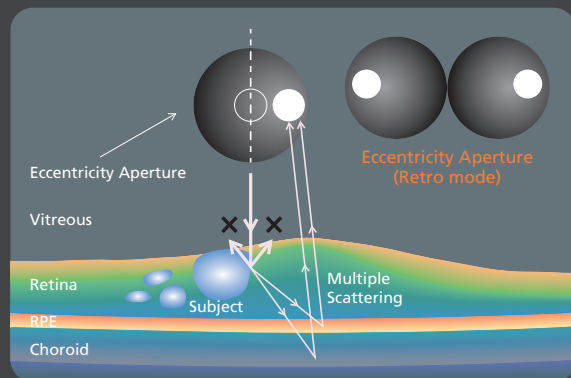


RGB triple detectors

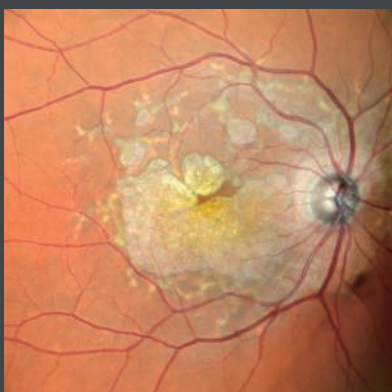
## Retro mode

Retro mode is a new non-invasive imaging technique for quick, highly sensitive detection of retinal and choroidal pathologies. In Retro mode, only the right or the left side of the aperture is open during the image acquisition.

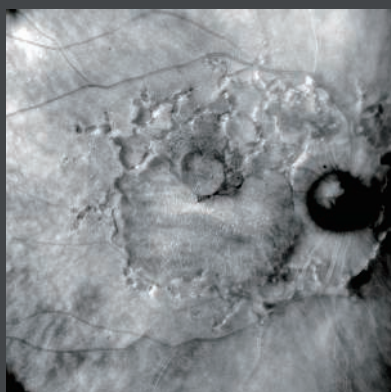
Pathology causes shadows that can be imaged with a pseudo-3D appearance.



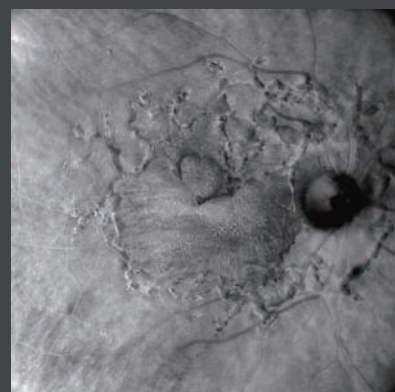
Retro mode



Color



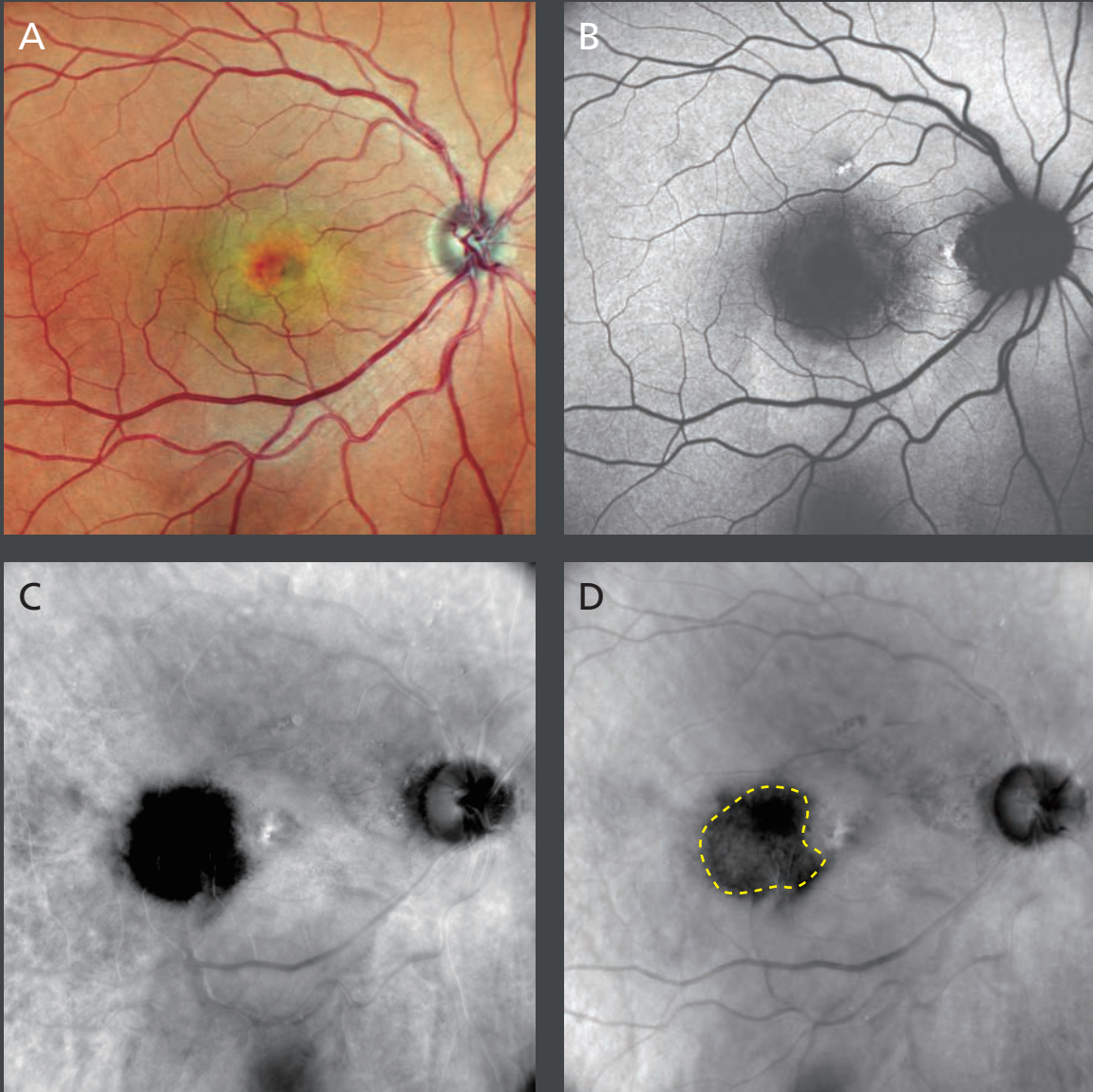
Retro mode left-deviated (DL) image



Retro mode right-deviated (DR) image

## Case 1: Choroidal Neovascularization (CNV)

Authors: Mariano Cozzi, MSc, Giovanni Staurenghi, MD, Luigi Sacco Hospital, University of Milan, Italy



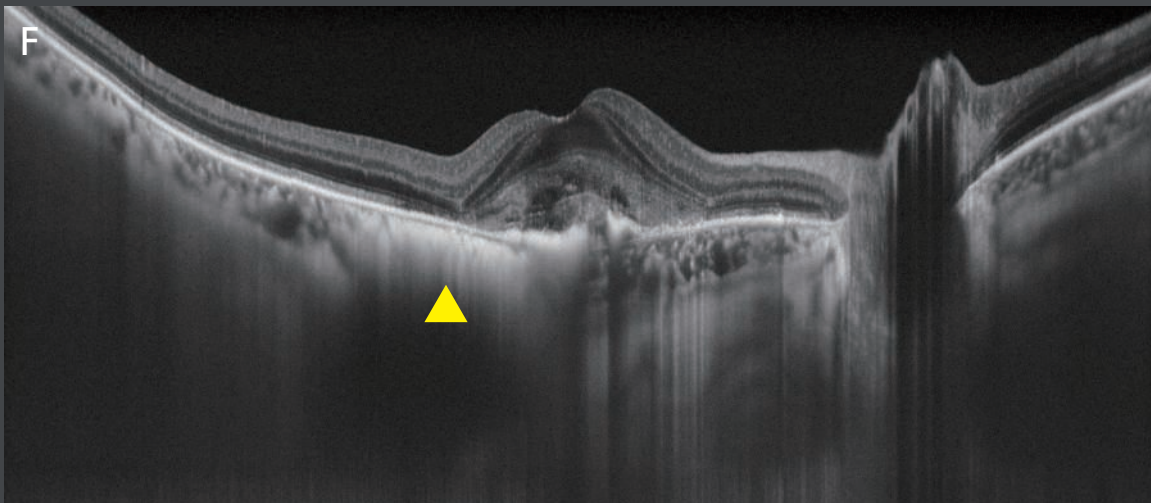
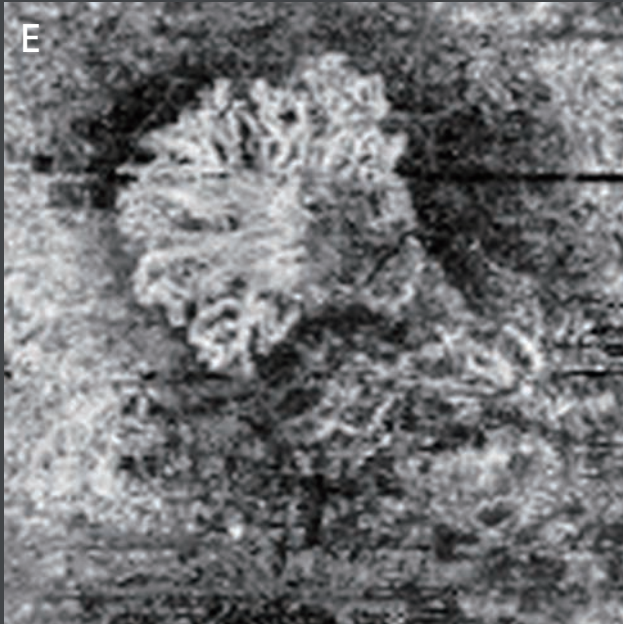
A 73-year-old male with CNV next to a choroidal nevus in the right eye.

**[A]** Confocal color image shows a central undefined lesion.

**[B]** Blue fundus autofluorescence reveals a hyper-autofluorescence area inferior to the fovea that represents subretinal fluid (SRF).

**[C,D]** Retro mode right-deviated (DR) and left-deviated (DL) dramatically highlight a dark area temporally to the fovea (dotted line) corresponding to the nevus. Drusen at the posterior pole are clearly visible.





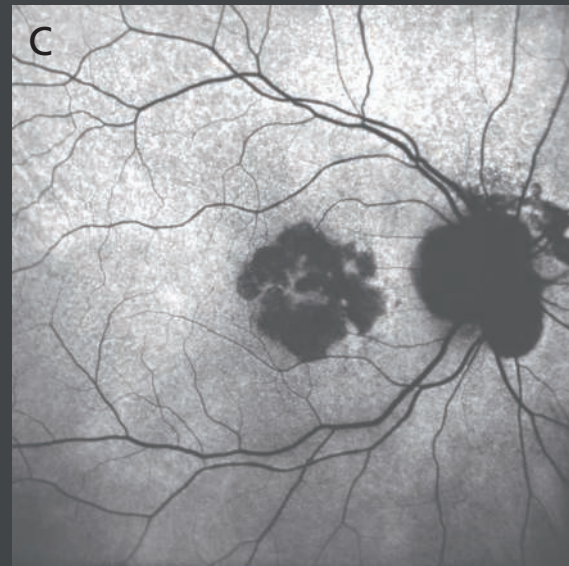
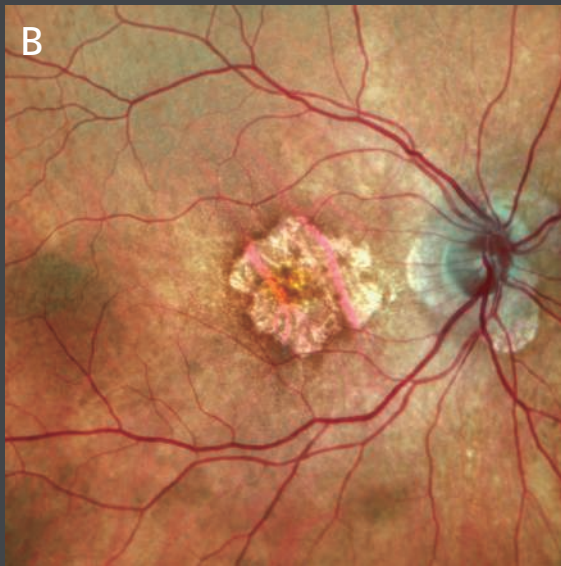
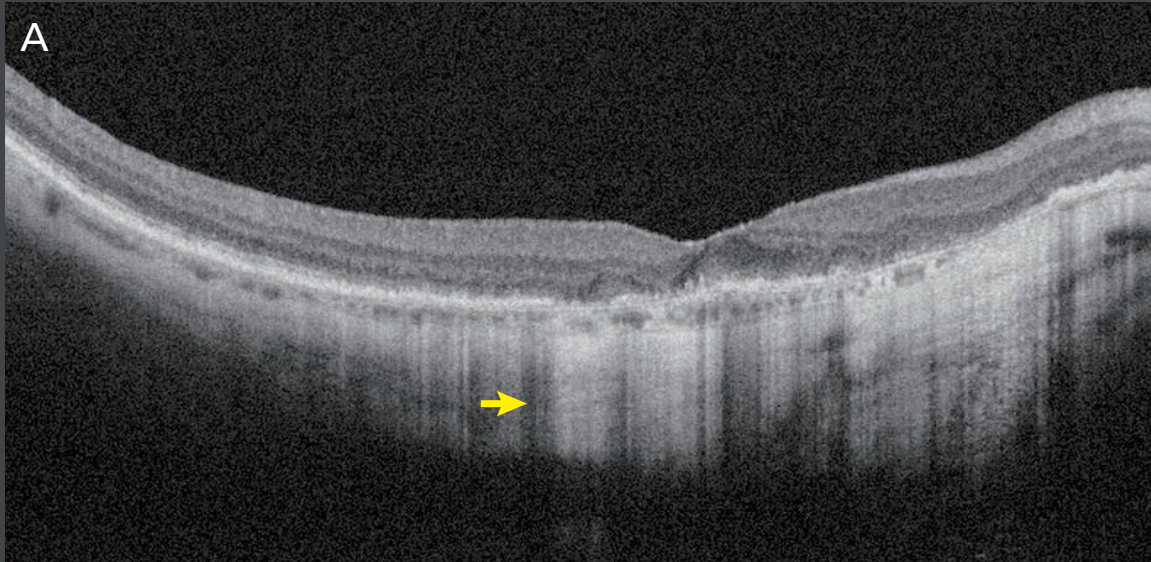
④ QA 3x3 mm OCT-Angiography centered on the fovea area shows the presence of a neovascular network. A slab of a section between the outer retina and choriocapillaris (ORCC) was selected to obtain the enface OCT-Angiography image.

④ QA an ultra fine choroidal 16.5 mm cross-sectional spectral-domain OCT image through the fovea (120X averaged) shows a flat hyper-reflective area below the RPE (yellow arrowhead) corresponding to the nevus. The presence of subretinal hyper-reflective material (SHRM) below the fovea represents CNV activity.

\*OCTA is not cleared by the FDA for distribution in the United States

**Case 2:**  
**Bilateral Geographic Atrophy (GA) Secondary to Age-related Macular Degeneration (AMD)**

*Authors: Mariano Cozzi, MSc, Giovanni Staurenghi, MD, Luigi Sacco Hospital, University of Milan, Italy*

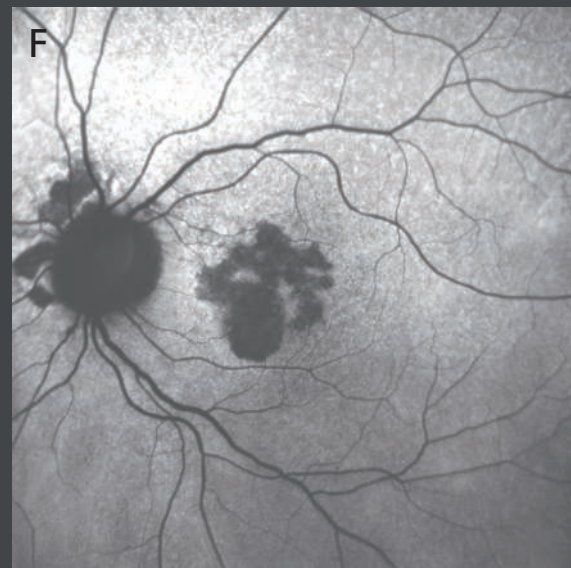
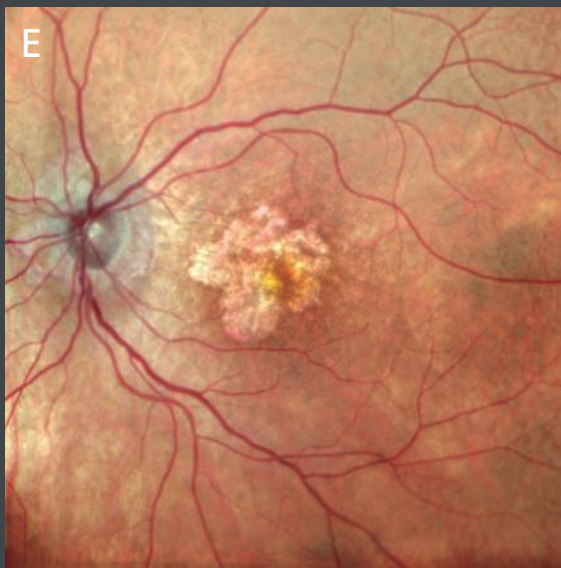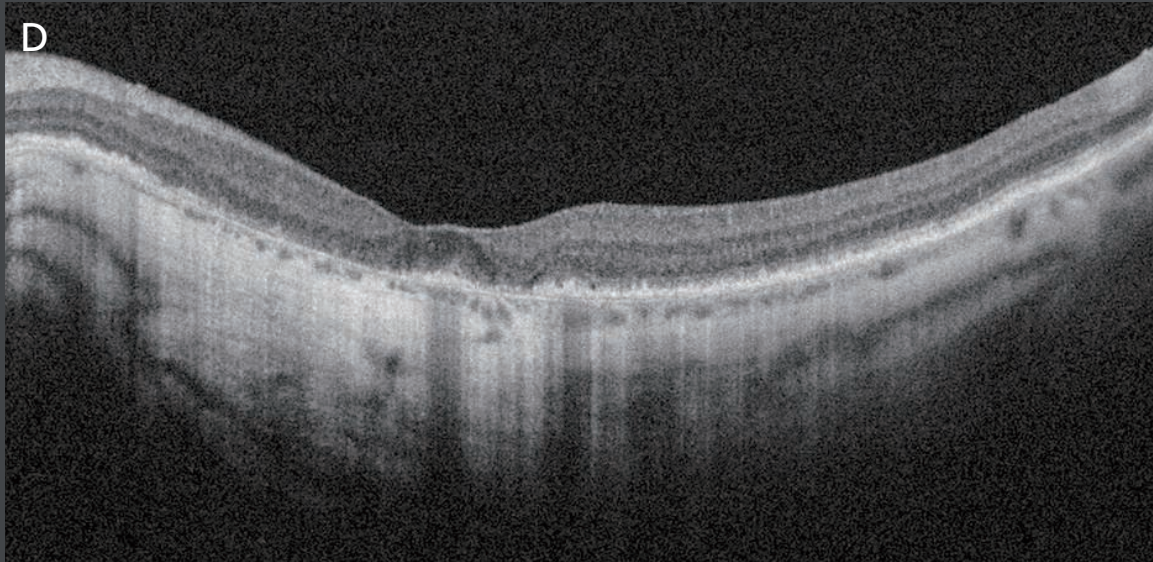


A 77-year-old female with bilateral GA secondary to AMD. Both right and left eyes are represented in the figures.

**[A,D]** Fine retinal cross-sectional spectral-domain OCT images through the fovea (10X averaged) show a thin choroid with areas of hyper-transmission of the signal (yellow arrow) corresponding to retinal pigment epithelium (RPE) and photoreceptors loss.

**[B,E]** Confocal color images show sharply demarcated areas of RPE hypopigmentation with the presence of underlying choroidal vessels.





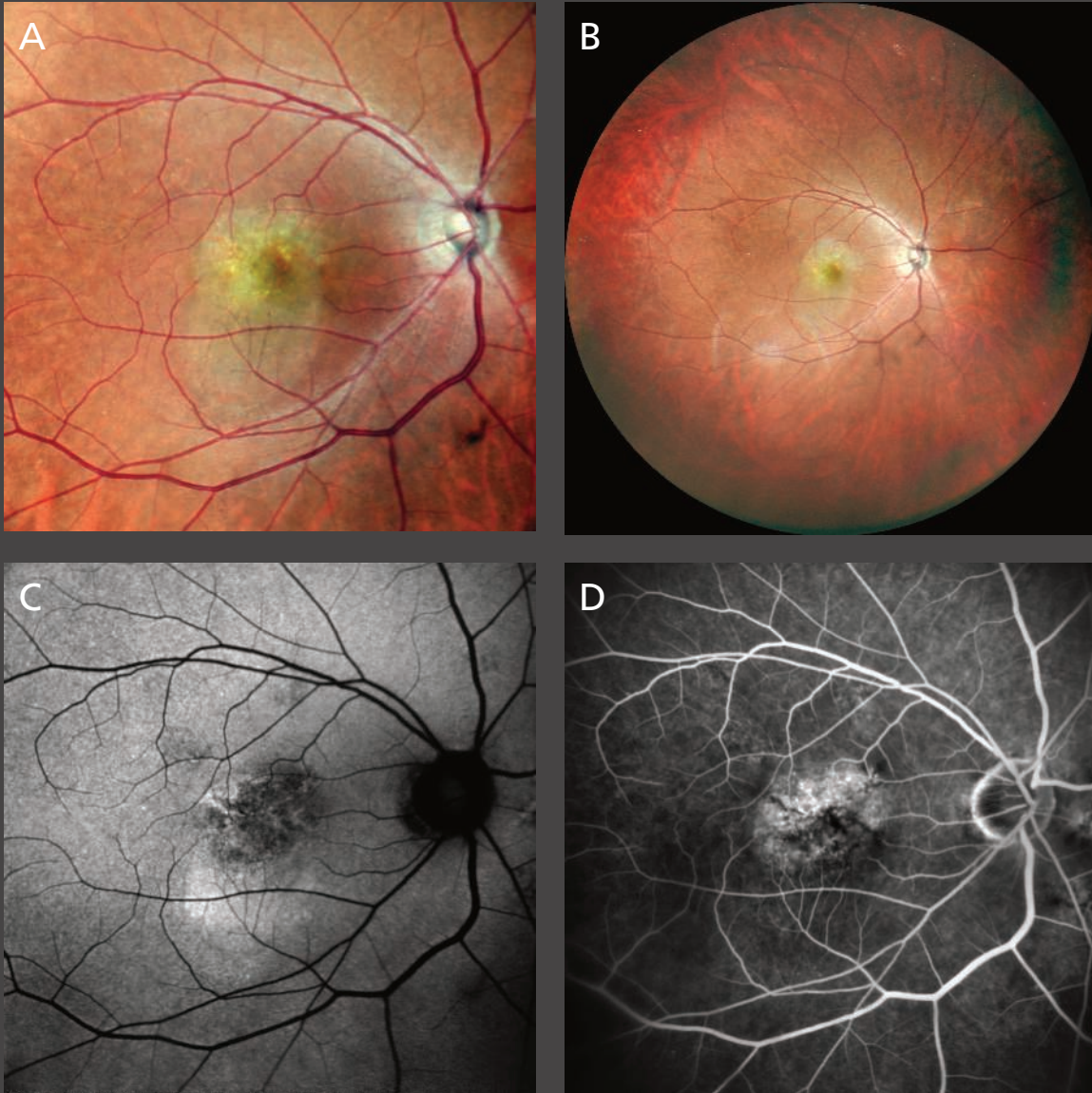
[C,F] Green fundus autofluorescence reveals irregular areas of decreased autofluorescence signal due to the lack of RPE cells containing lipofuscin. Peripapillary areas of atrophy are visible due to the wide field of view (89°).



### Case 3:

## Choroidal Neovascularization Associated with Age-related Macular Degeneration (AMD) with Central Serous Chorioretinopathy (CSCR)

Authors: Giulia Corradetti, MD, Srinivas Sadda, MD, Doheny Eye Institute, UCLA, USA

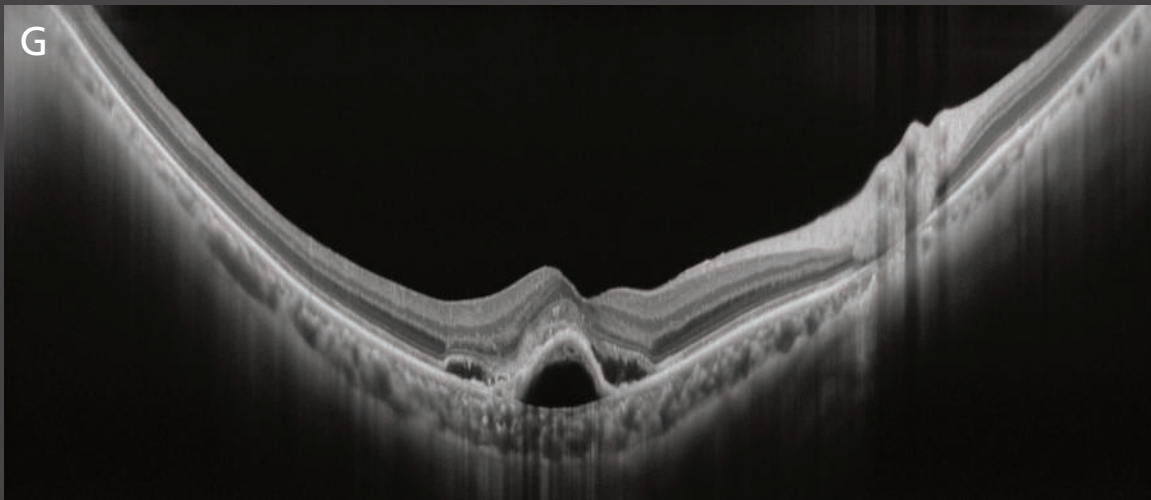
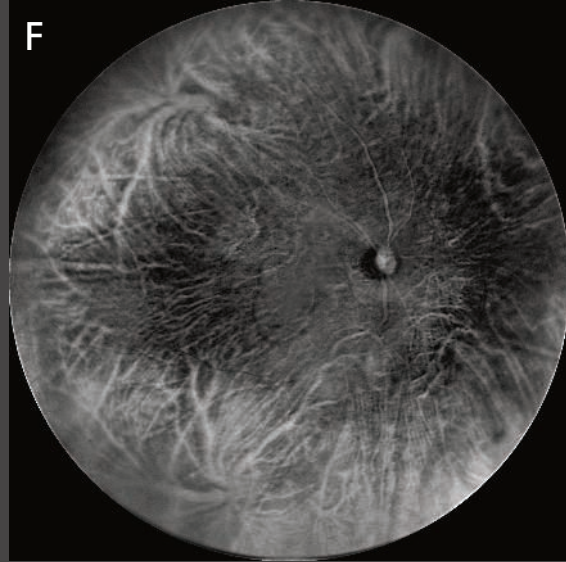
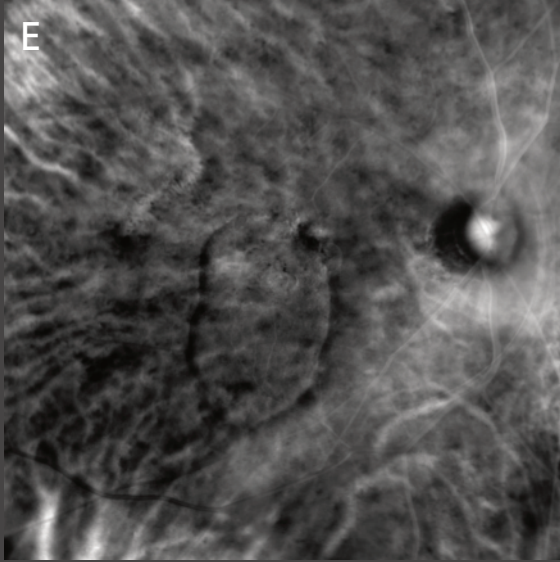


Multimodal imaging of a case of choroidal neovascularization associated with AMD with some CSCR-like features in an 85-year-old male.

**[A,B]** Standard and ultra wide field color fundus photographs captured with the Mirante confocal scanning laser ophthalmoscopy are presented using three different channels (blue, green, and red) with central angles of 89° and 163°, respectively. Both images show a smooth and well-circumscribed yellowish fibrovascular pigment epithelial detachment (PED) involving the central macula.

**[C]** Green autofluorescence shows a central area of mottled hypo-autofluorescence highlighting the altered retinal pigment epithelium in the region of the PED, with adjacent hyper-autofluorescence inferiorly corresponding to the subretinal fluid.

**[D]** Early phase fluorescein angiography shows irregular, stippled hyper-fluorescence corresponding to the fibrovascular PED.



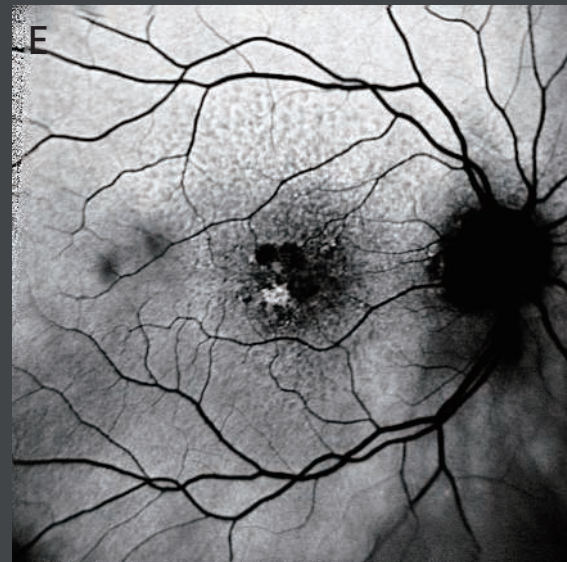
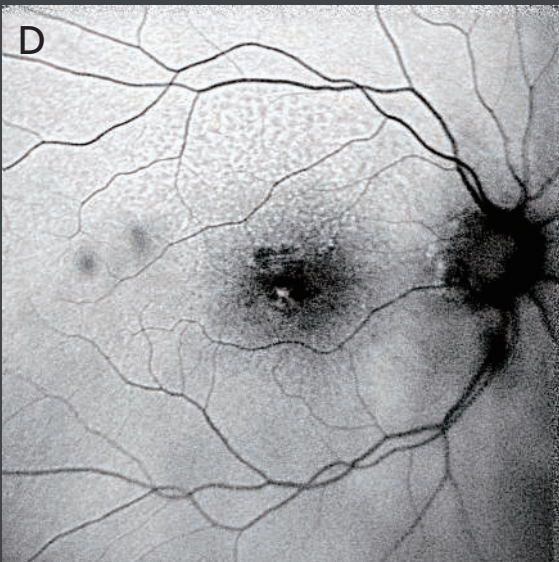
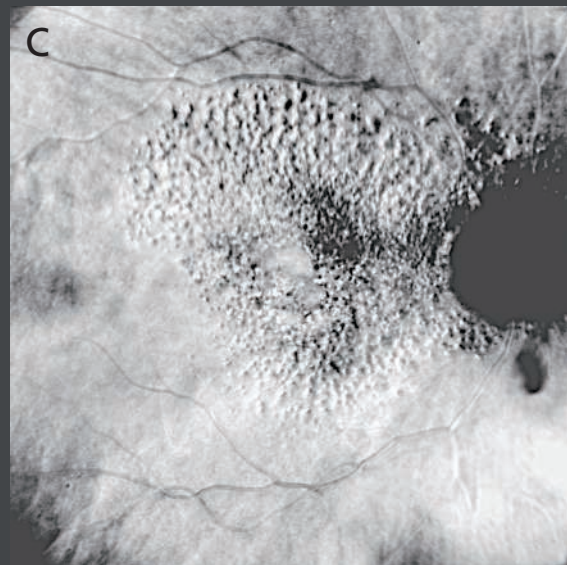
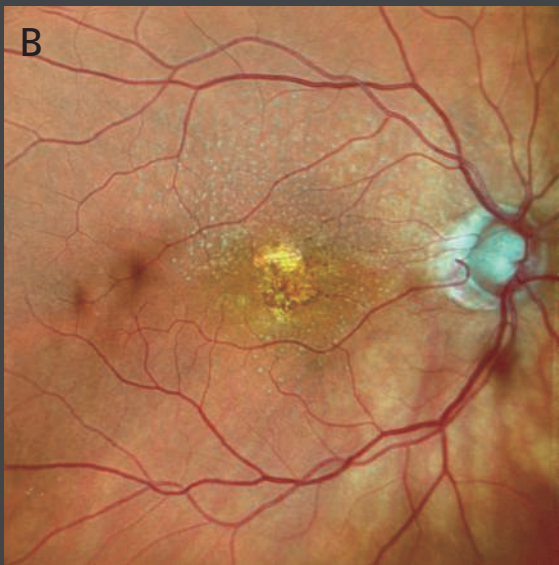
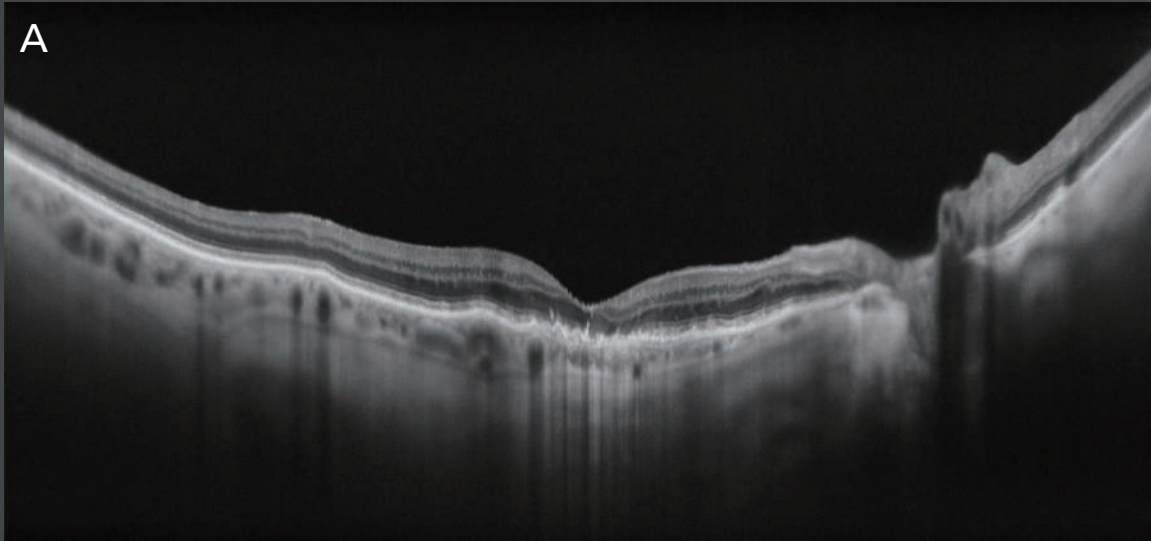
**[E,F]** Retro mode left-deviated (DL), standard and ultra wide field images, respectively, show a vertical oval-shaped slightly hyper-reflective region with a rim of hypo-reflectivity corresponding to the neurosensory detachment. The vertically-oblong shape suggests the gravitational nature of the fluid distribution. The Retro mode technology, using an eccentric confocal aperture, provides additional contrast to display the fluid and its extent.

**[G]** An ultra fine cross-sectional spectral-domain OCT image through the foveal center (120X averaged) demonstrates a fibrovascular PED with a secondary elevation of the overlying retina and subretinal fluid. Note, the internal characteristics of the PED are visible, with fibrovascular tissue at the apex of the PED and subretinal pigment epithelium fluid at the base. The full extent of the choroid is visualized and appears to be thick given the patient's age.



**Case 4:**  
**Reticular Pseudodrusen for Age-related Macular Degeneration (AMD)**

*Authors: Giulia Corradetti, MD, Srinivas Sadda, MD, Doheny Eye Institute, UCLA, USA*



A case of reticular pseudodrusen in an 89-year-old female followed for AMD.

**[A]** Ultra fine 16.5 mm spectral-domain OCT B-scan (120X averaged) through the center of the macula shows a thin choroid and evidence of numerous hyper-reflective subretinal drusenoid deposits (SDD) above the RPE band.

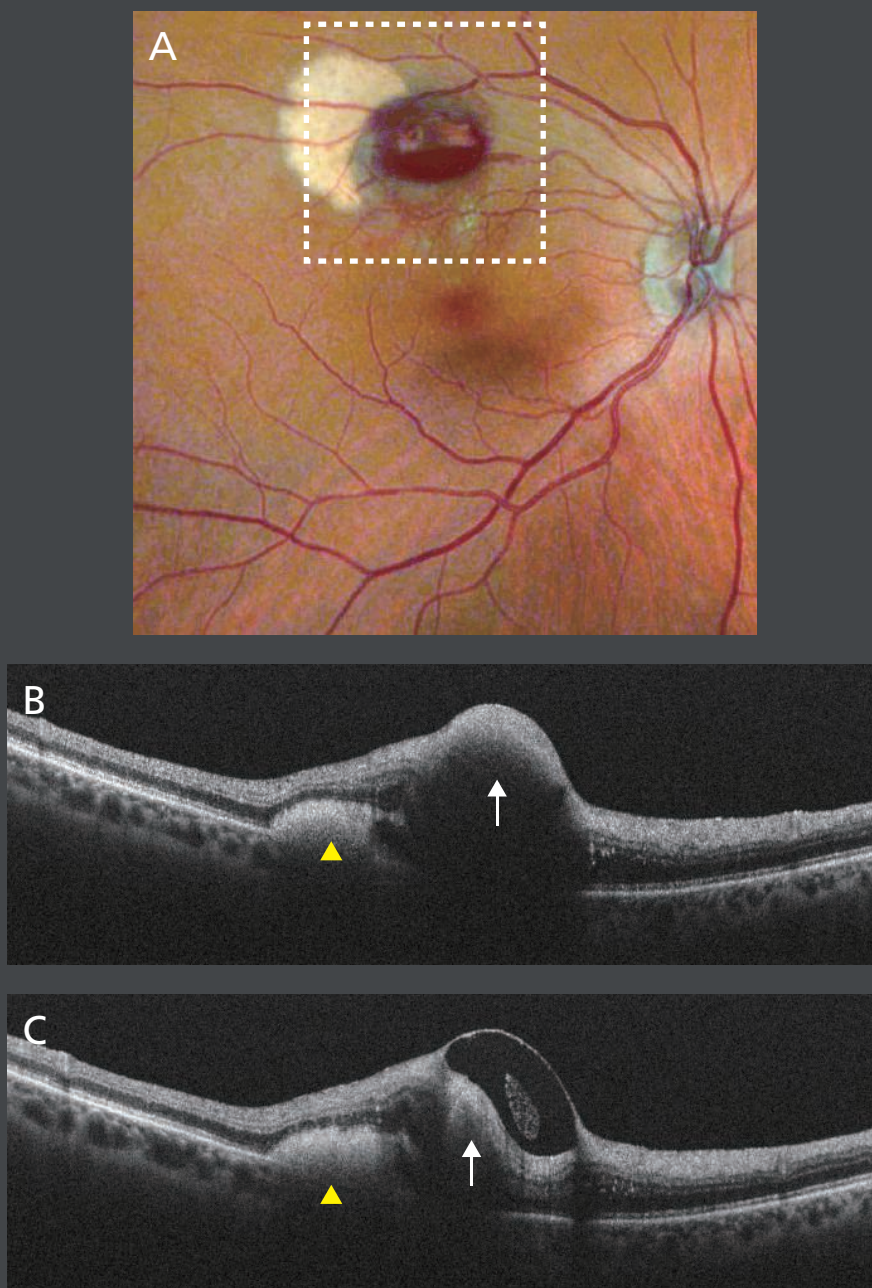
**[B]** Confocal SLO color fundus photograph clearly highlights the SDD/reticular pseudodrusen which are normally difficult to observe on standard flash color photographs. Note the interlacing pattern of the yellow-white subretinal material, typical of reticular pseudodrusen and slightly lighter compared to other types of drusen.

**[C]** Retro mode illumination imaging dramatically and sharply delineates the extent of these pseudodrusen, which are normally not well-demarcated and difficult to quantify.

**[D,E]** Comparison of blue and green light autofluorescence, respectively. The fundus autofluorescence shows dots of hypo-autofluorescence surrounded by a reticular pattern of hyper-autofluorescence. The contrast for identifying the pseudodrusen appears to be better with the green light autofluorescence.

## Case 5: Retinal Arterial Macroaneurysm (RAM)

Authors: Federica Ristoldo, BSc, Mariano Cozzi, MSc, Giovanni Staurenghi, MD, Luigi Sacco Hospital, University of Milan, Italy

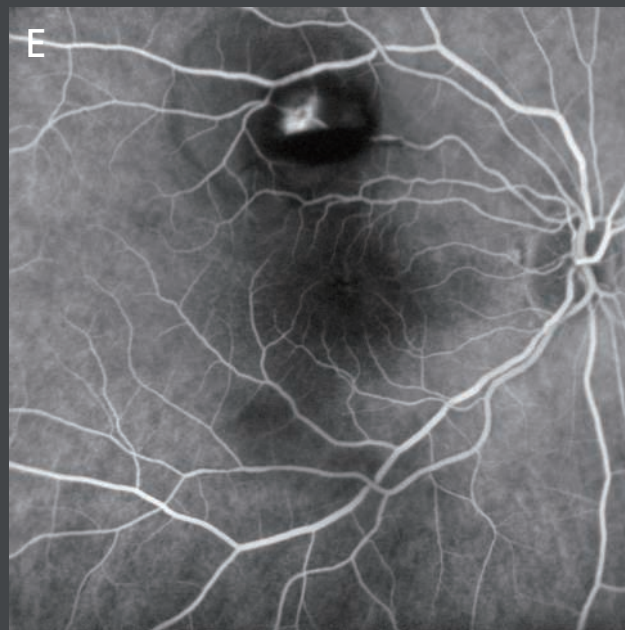
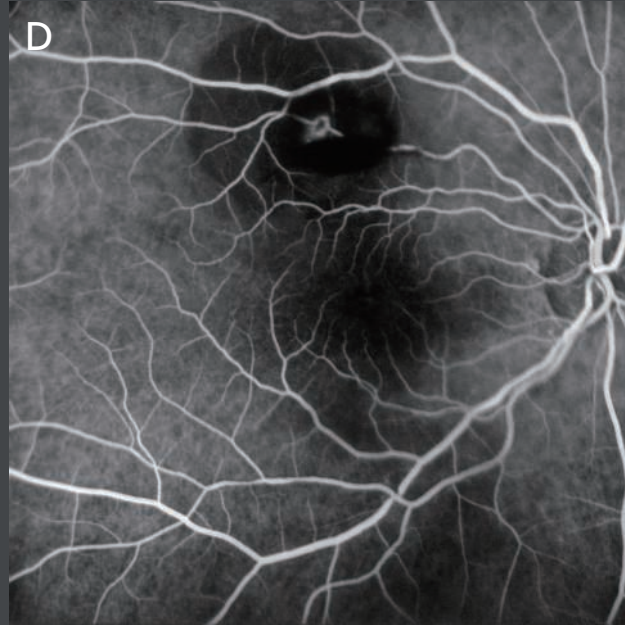


A 76-year-old female was referred to our clinic for a RAM in the right eye.

**[A]** Confocal color image shows a pre-retinal hemorrhage along the superior vascular arcade with a whitish area next to it representing the long-standing blood.

**[B,C]** Fine retinal cross-sectional spectral-domain OCT images acquired in two different areas show some hyper-reflective material below the neuroretina (yellow arrowheads and white arrows) which consists of the old blood. A different reflective material located within/above the retinal layers represents a recent hemorrhage.

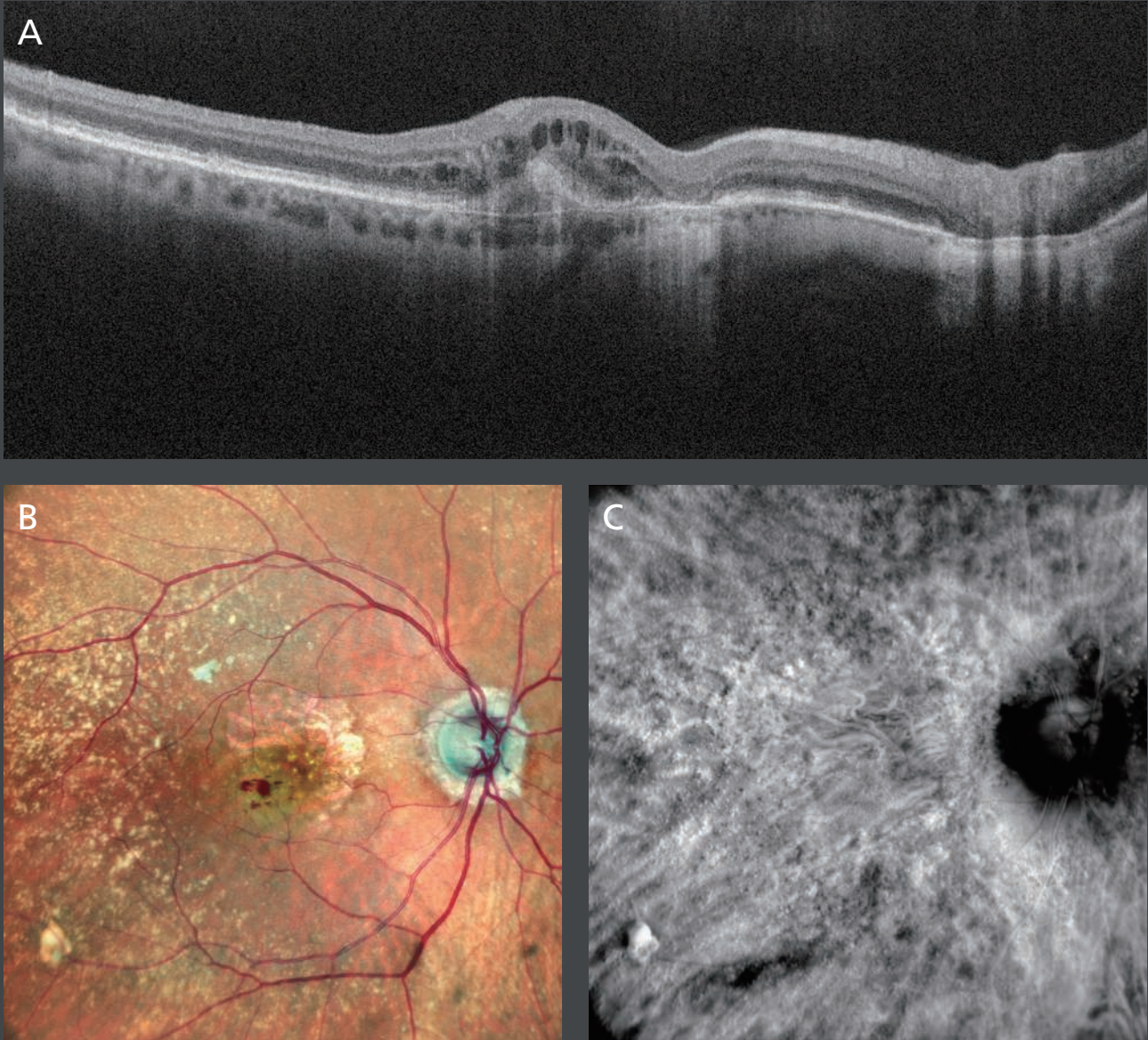




**[D,E]** Fluorescein angiography in the filling phase highlights the focal hyper-fluorescent rounded dilation within the artery with evidence of leakage in the intermediate phase of the exam.

## Case 6: Retinal Angiomatous Proliferation (RAP)

Authors: Mariano Cozzi, MSc, Giovanni Staurenghi, MD, Luigi Sacco Hospital, University of Milan, Italy



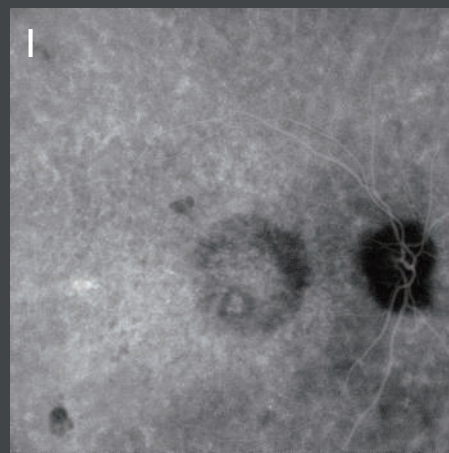
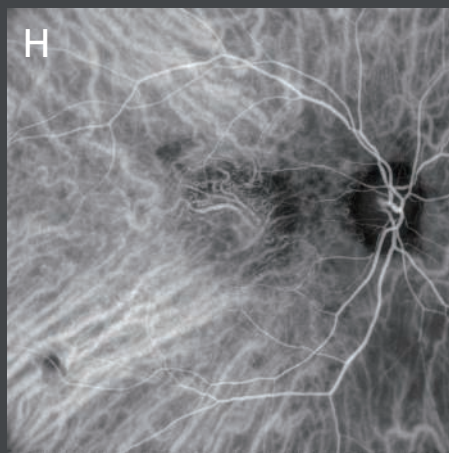
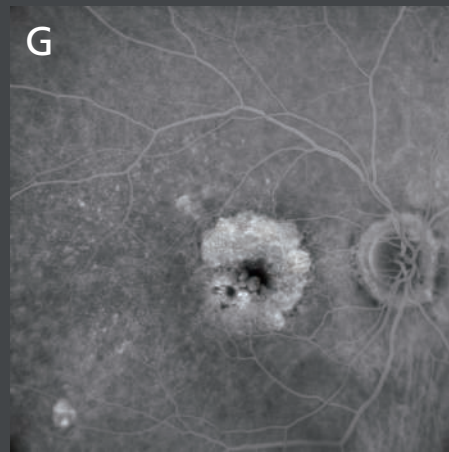
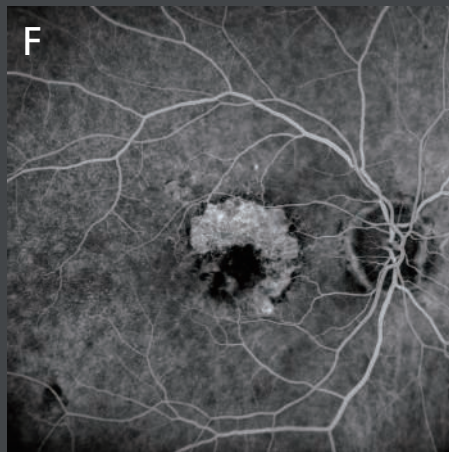
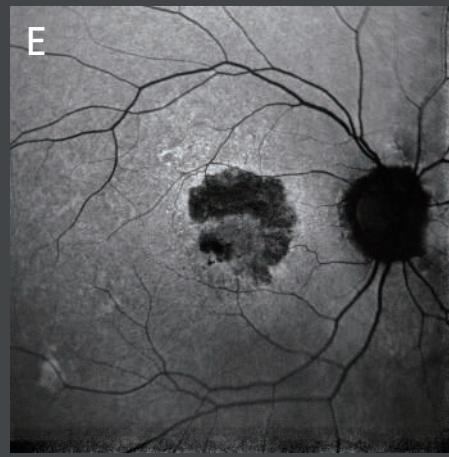
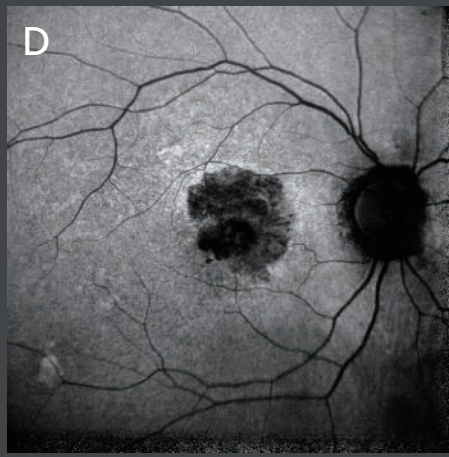
Multimodal imaging in a case of active RAP in a 79-year-old female. Each imaging modality highlights different aspects of the disease. A dye-based exam was necessary to better characterize the lesion.

**[A]** High definition cross-sectional OCT B-scan shows an area of enhanced signal through the choroid due to RPE atrophy, intraretinal cysts, and a back shadowing signal related to the presence of an intraretinal hemorrhage.

**[B]** Color confocal image dramatically reveals the presence of multiple intraretinal hemorrhages, large drusen fulfilling the entire posterior pole, and RPE atrophy without foveal involvement.

**[C]** Retro mode infrared illumination image highlights the topographic distribution of drusen.





**[D]** Blue autofluorescence shows a black autofluorescence signal centered on the macula, precluding a clear definition of the fovea from either the atrophy or the hemorrhages.

**[E]** Green autofluorescence allows better appreciation of the atrophy from the hemorrhage. This exam confirms the foveal sparing of the atrophy.

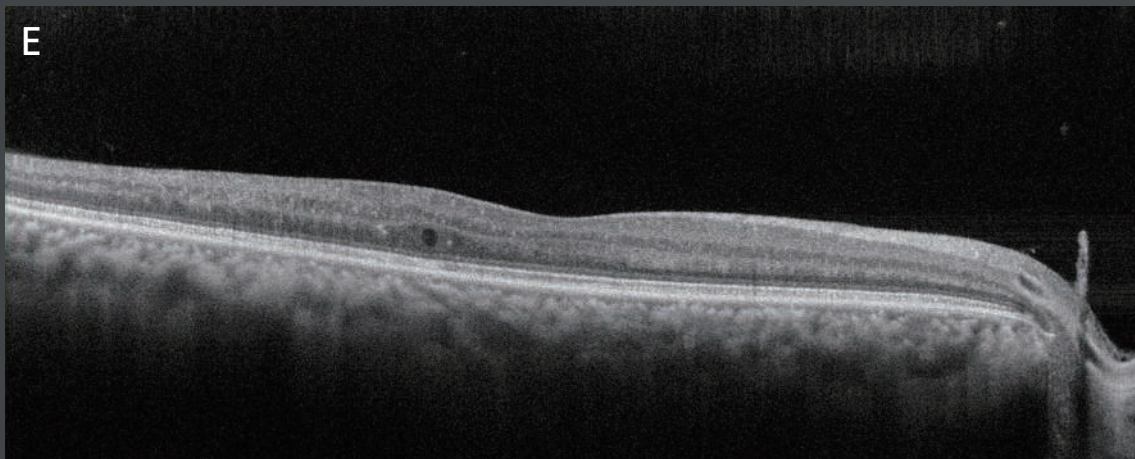
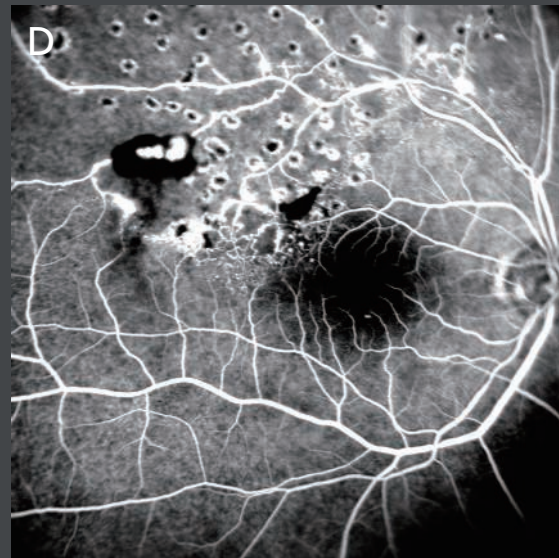
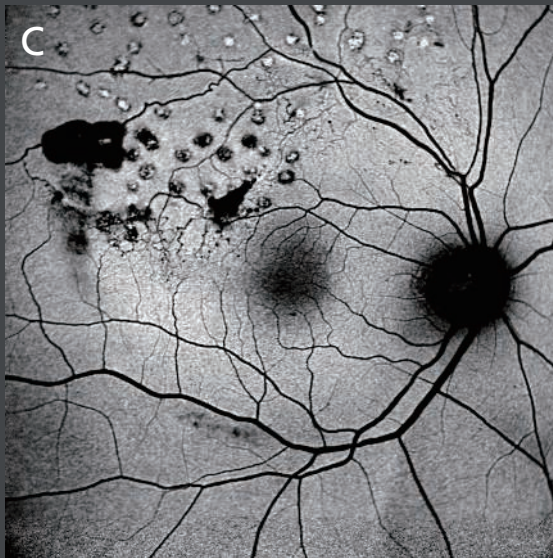
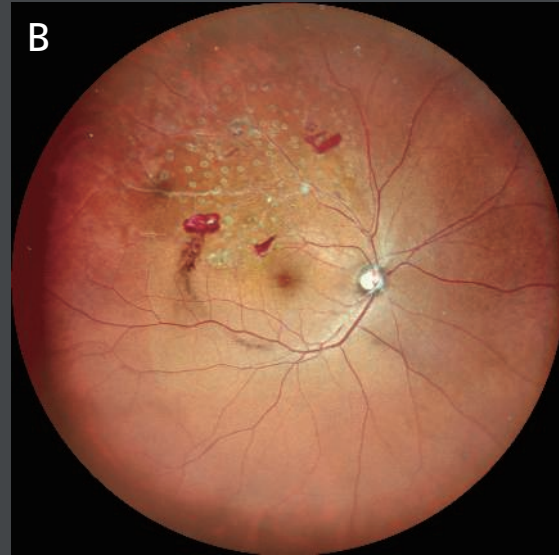
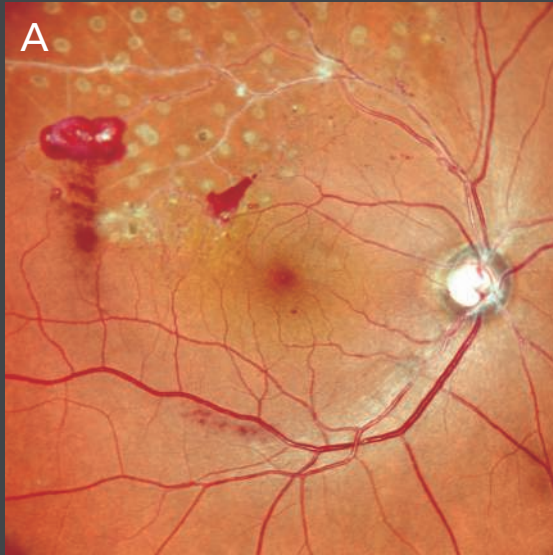
**[F,G]** Early and late phase of fluorescein angiography showing leakage and cysts pooling in the late phase of the exam. The window effect of the RPE atrophy is also visible in both phases of the exam.

**[H,I]** Early and late phase of indocyanine green angiography show the presence of the anastomosis with moderate leakage in the late phase of the exam.



## Case 7: Branch Retinal Vein Occlusion (BRVO)

Authors: Giulia Corradetti, MD, Srinivas Sadda, MD, Doheny Eye Institute, UCLA, USA



Multimodal imaging in a 55-year-old male patient with BRVO.

**[A,B]** Standard and ultra wide field color confocal fundus photographs with central angles of 89° and 163°, respectively. Both color photographs clearly show characteristic features of a supero-temporal BRVO in the right eye. Note the intraretinal hemorrhages as well as pre-retinal hemorrhages suggesting underlying retinal neovascularization. Sclerotic retinal vessels suggestive of non-perfusion can also be seen. Scatter pan-retinal photocoagulation scars can be seen in this region.

**[C]** Hemorrhages appear hypo-autofluorescent on green light autofluorescence.

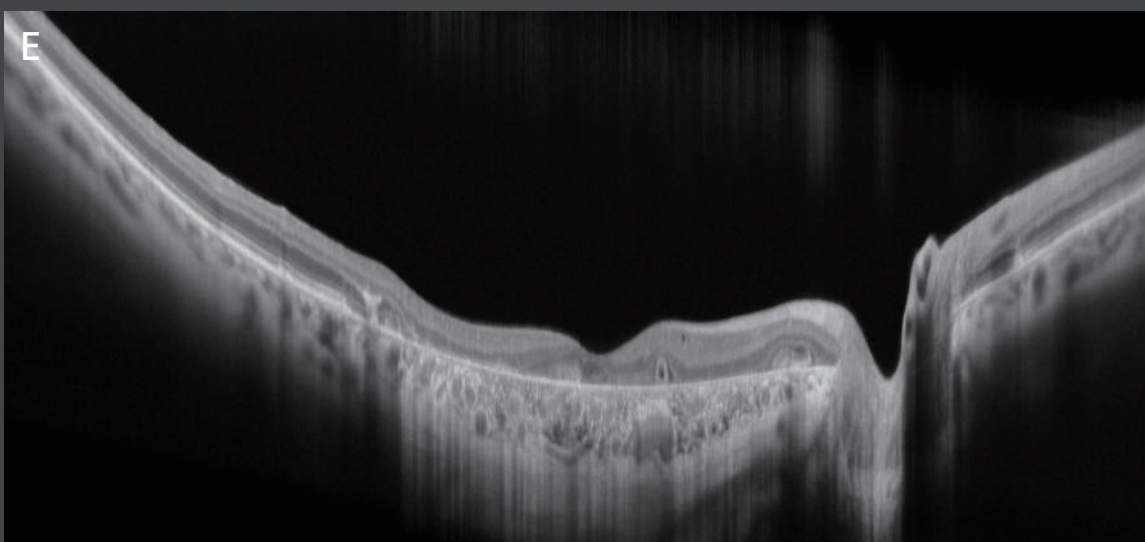
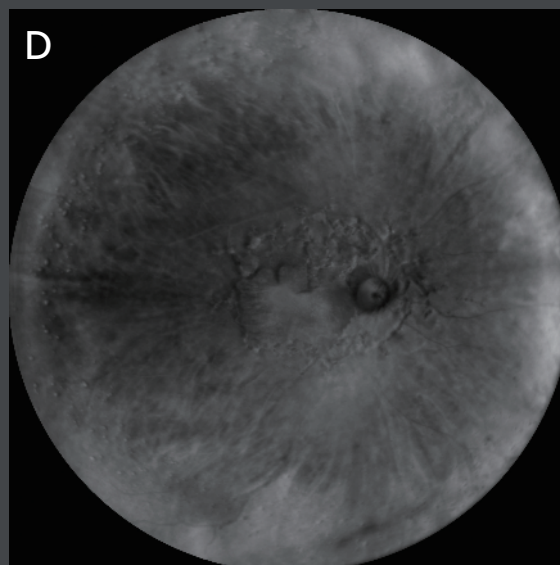
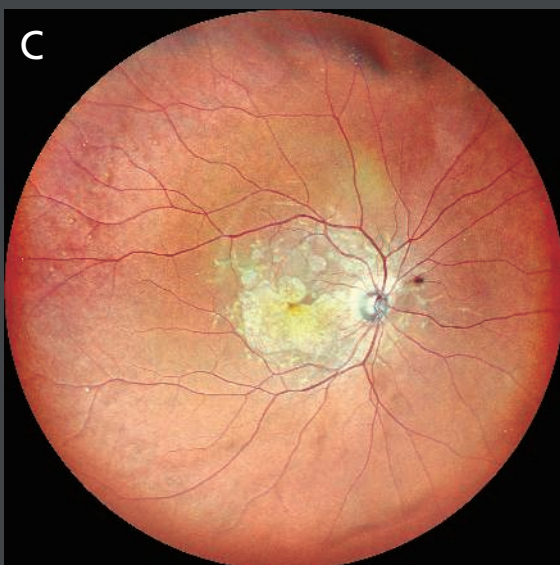
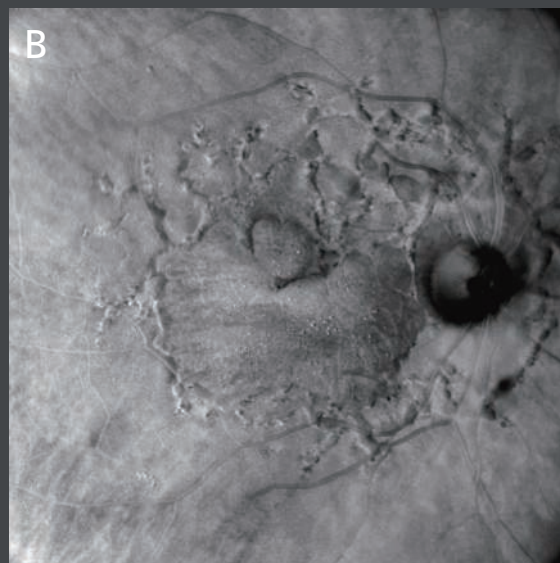
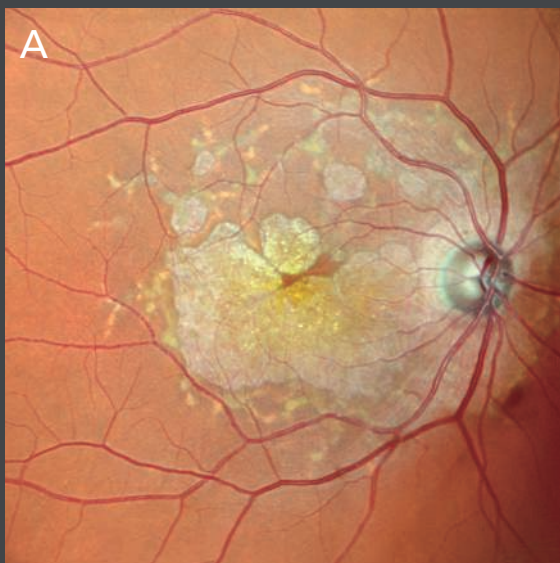
**[D]** Fluorescein angiography demonstrates extensive capillary non-perfusion with laser scars present in these regions. Additional areas of untreated non-perfusion can be seen. Regions of fluorescein leakage, partially obscured by hemorrhage, are observed and consistent with persistent active neovascularization, suggesting that additional therapy is warranted.

**[E]** Wide angle spectral-domain OCT superior to the foveal center shows thinning of the temporal macula consistent with the ischemia.



## Case 8: Stargardt Disease Related to Mutations in the ABCA4 Gene

Authors: Giulia Corradetti, MD, Srinivas Sadda, MD, Doheny Eye Institute, UCLA, USA



A 55-year-old male with Stargardt disease related to mutations in the ABCA4 gene.

**[A]** Color fundus photograph shows the polychromatic sheen of the macular atrophy referred to as a "beaten-bronze" appearance, as well as flecks surrounding the atrophy extending towards the arcades.

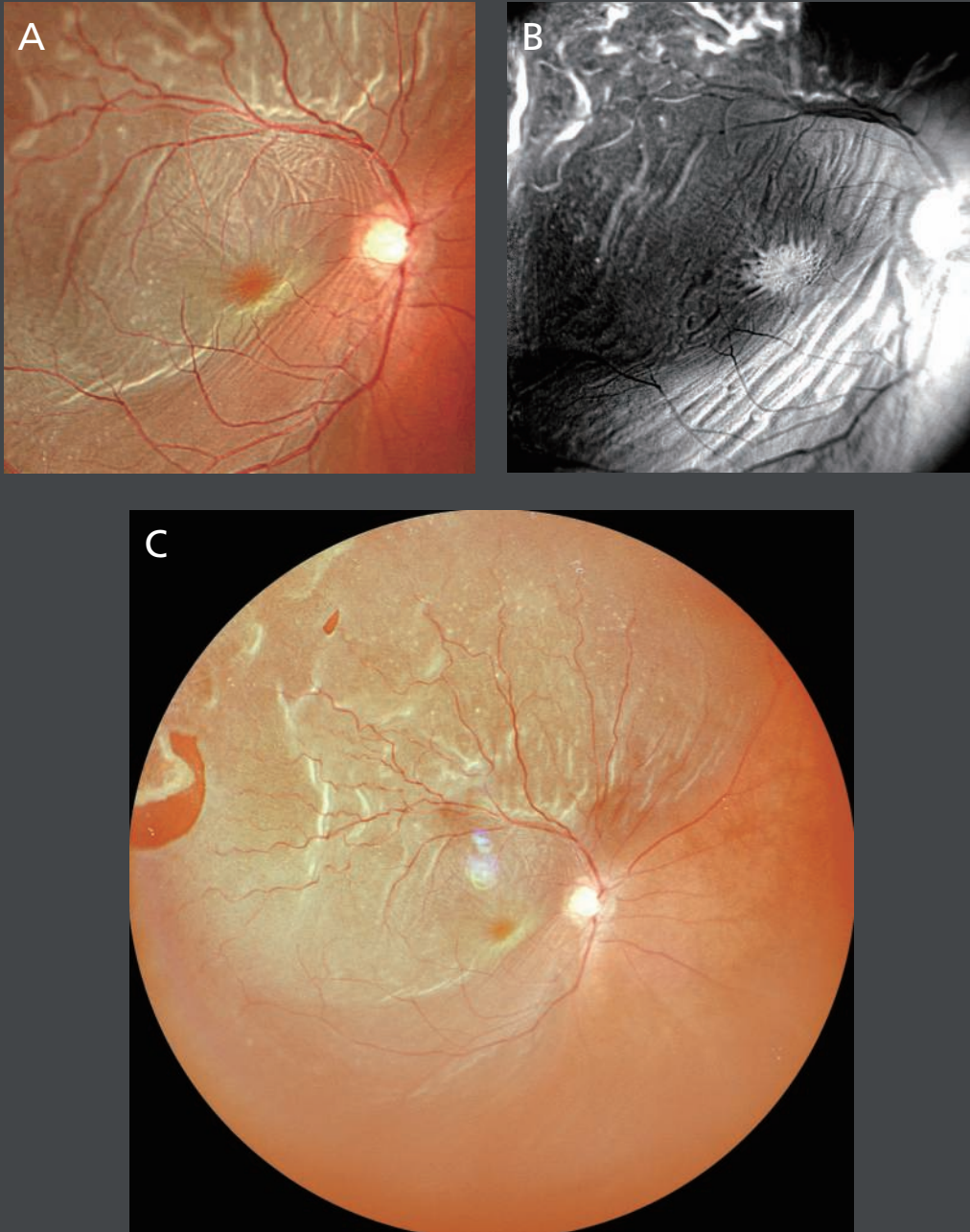
**[B]** Retro mode right-deviated (DR) illumination image clearly highlights the topographic distribution of the flecks in the paramacular region and the well-demarcated atrophy in the central macula.

**[C,D]** Ultra wide field 163° color [C] and Retro mode [D] images centered on the macula. Both modalities clearly show the central atrophy and paramacular flecks, but in addition, punctate yellowish lesions resembling drusen are visible in the far periphery, especially temporally. These lesions are best observed on the Retro mode images [D].

**[E]** An ultra fine 16.5 mm cross-sectional spectral-domain OCT image through the foveal center (120X averaged) showing the central complete outer retina and retinal pigment epithelium atrophy. The full extent of the choroid is visible throughout.

## Case 9: Bilateral Rhegmatogenous Retinal Detachment in a High Myope

Authors: Giulia Corradetti, MD, Srinivas Sadda, MD, Doheny Eye Institute, UCLA, USA

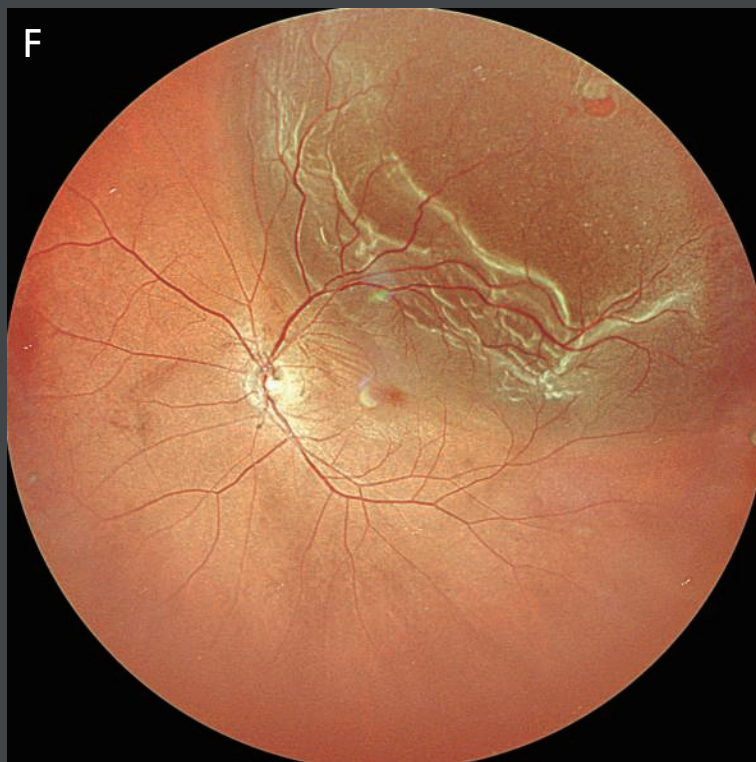
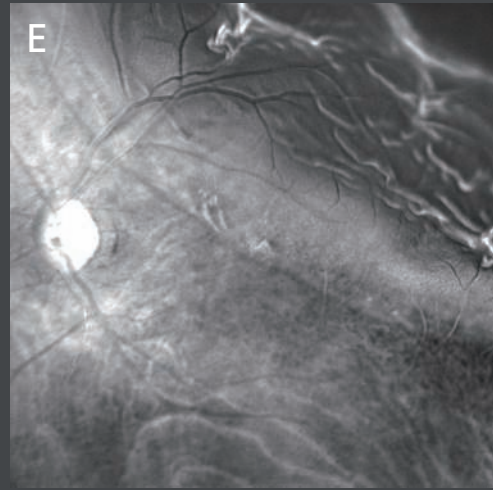
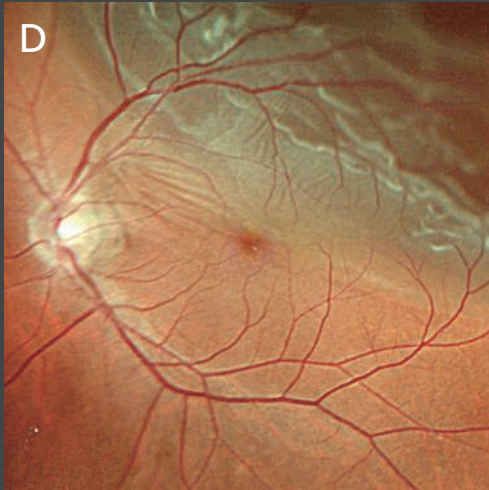


A case of bilateral rhegmatogenous retinal detachment in a high myopic 45-year-old male.

**[A,D]** Standard color fundus photographs clearly show the retinal detachment with prominent corrugations/retinal folds. The detachment in the right eye clearly involves the fovea whereas the left appears to be just about the foveal center.

**[B,E]** Retro mode illumination imaging dramatically highlights the retinal folds, but also highlights the central cystoid macular edema in the right eye which was difficult to discern on the color photos alone.

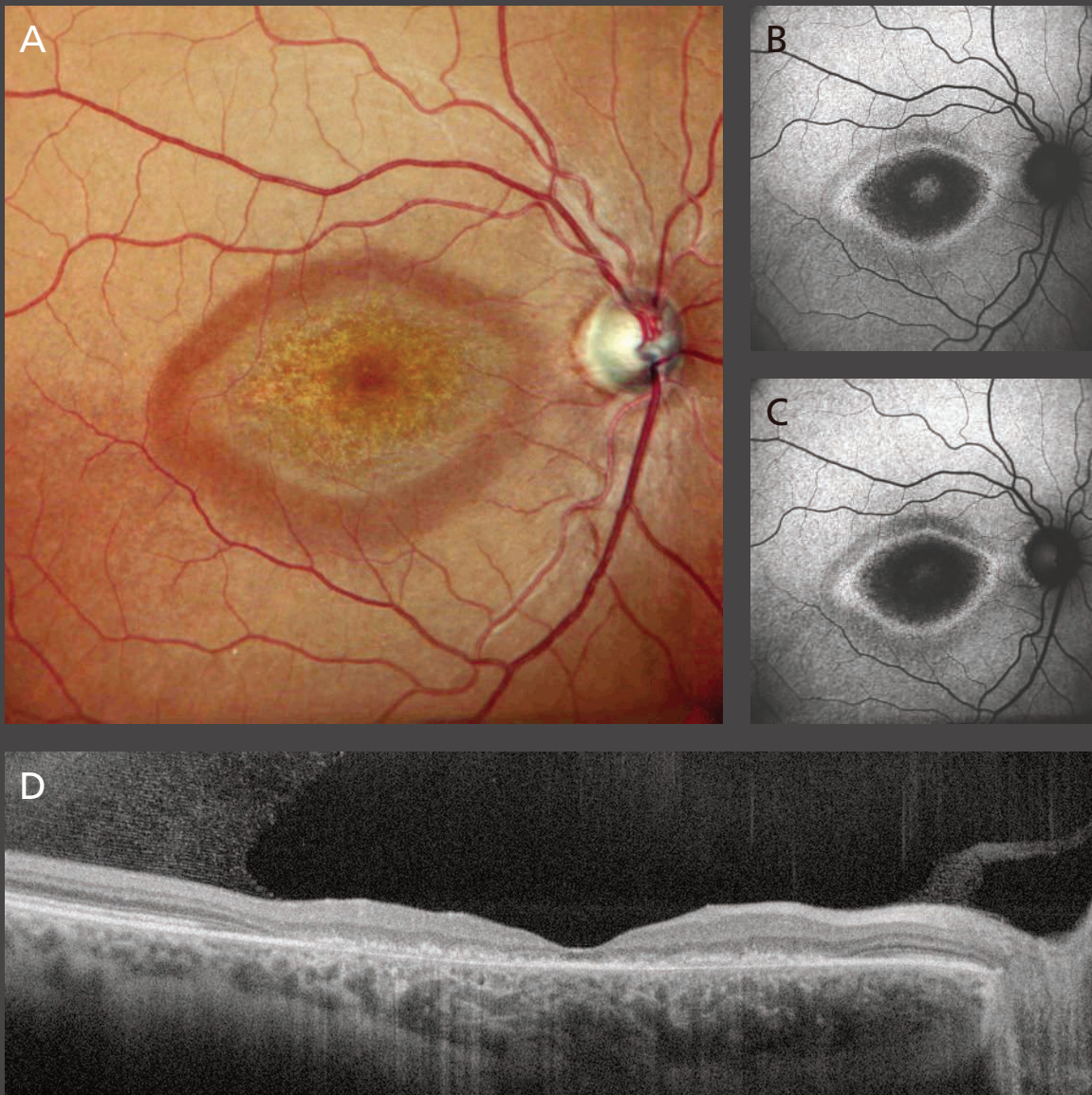




[C,F] Ultra wide field color fundus photographs illustrate the full extent of the superior detachments in both eyes as well as the peripheral retinal breaks in both eyes (including both a large horseshoe tear and a smaller break in the right eye).

## Case 10: Hydroxychloroquine Retinopathy

Authors: Mariano Cozzi, MSc, Giovanni Staurenghi, MD, Luigi Sacco Hospital, University of Milan, Italy

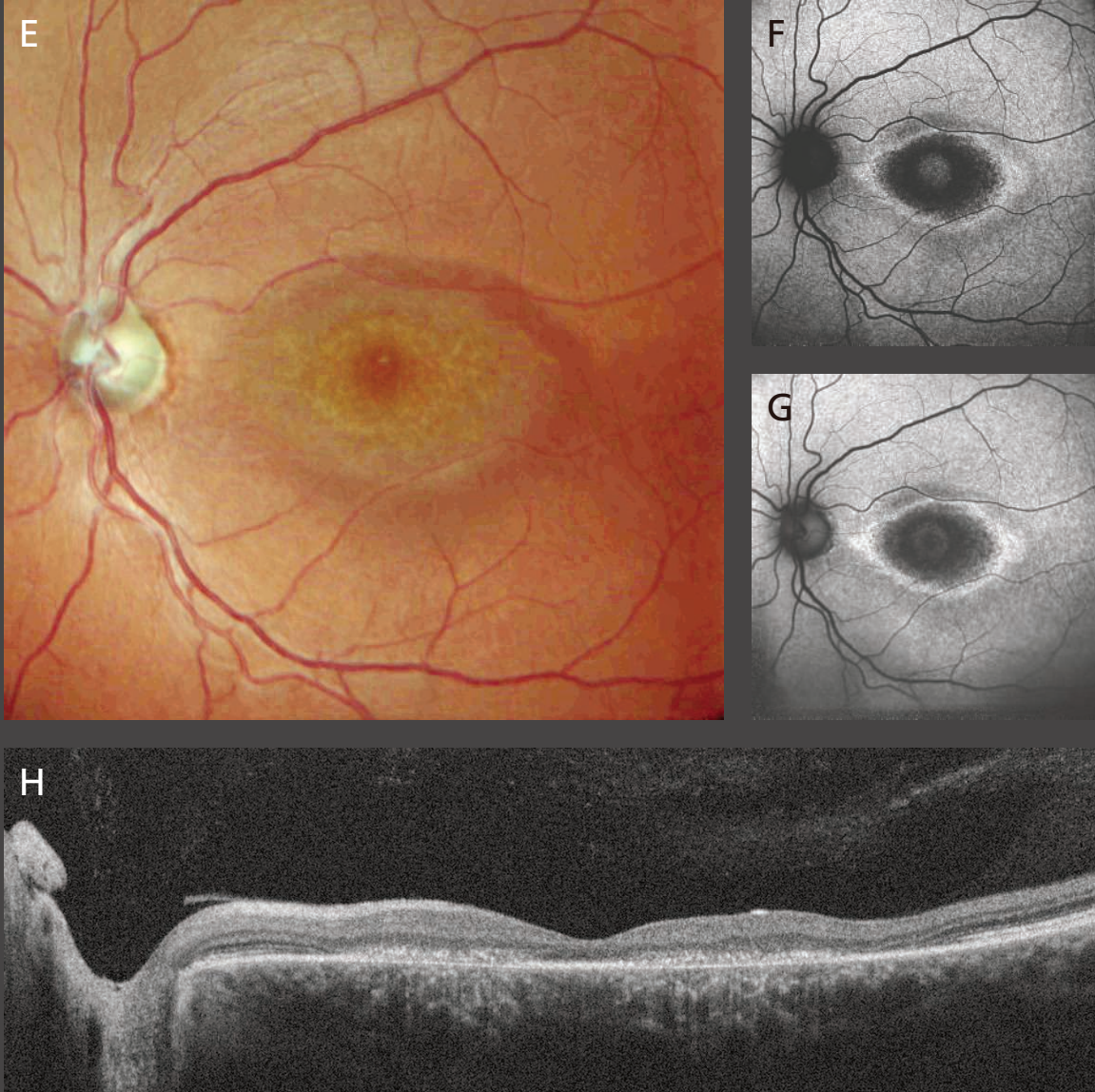


A 42-year-old female affected with hydroxychloroquine retinopathy. Both right and left eyes are represented in the figures.

**[A,E]** Confocal color images represent a symmetric pronounced bull's eye maculopathy.

**[B,C,F,G]** Fundus autofluorescence in green and blue highlights a symmetric macular atrophy with a hyper-autofluorescent ring surrounding the dark area. In green fundus autofluorescence, a signal from preserved central RPE cells is barely visible.

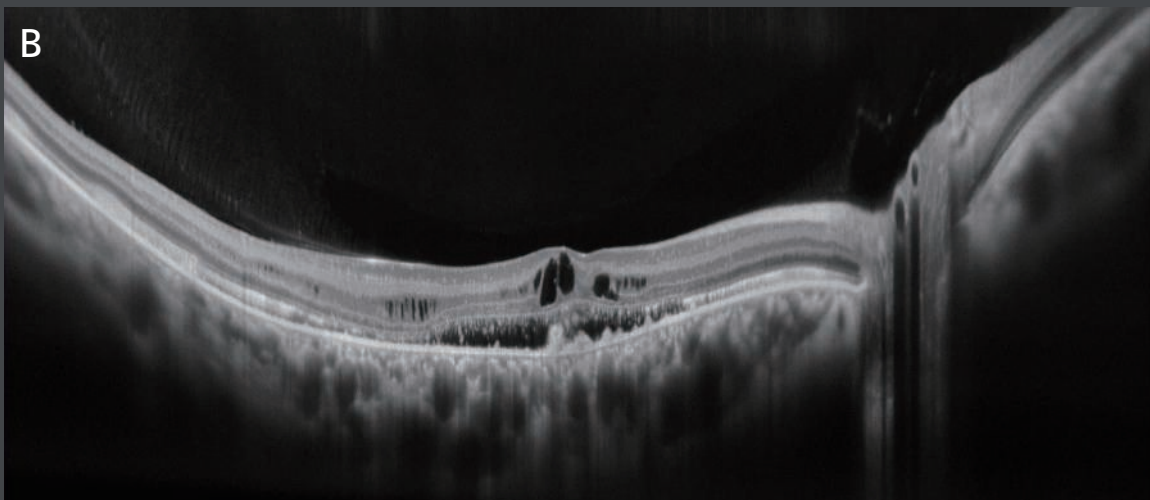
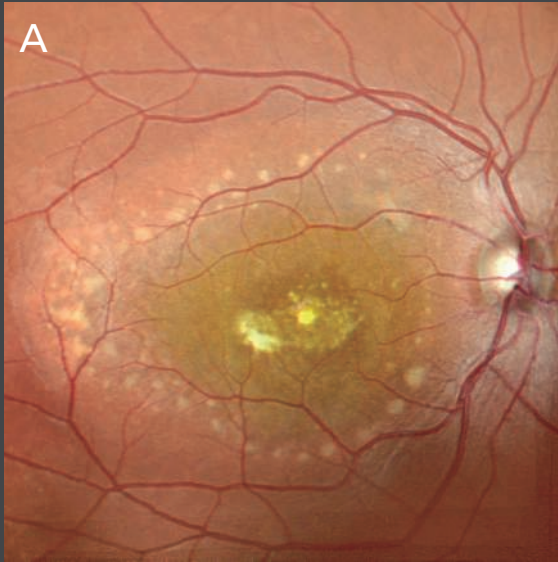



[D,H] Fine retinal cross-sectional spectral-domain OCT images through the fovea (10X averaged) show a thinning of retinal layers in the macula and a complete disruption of the outer retinal structures.

## Case 11: Best Vitelliform Macular Dystrophy

Authors: Giulia Corradetti, MD, Srinivas Sadda, MD, Doheny Eye Institute, UCLA, USA

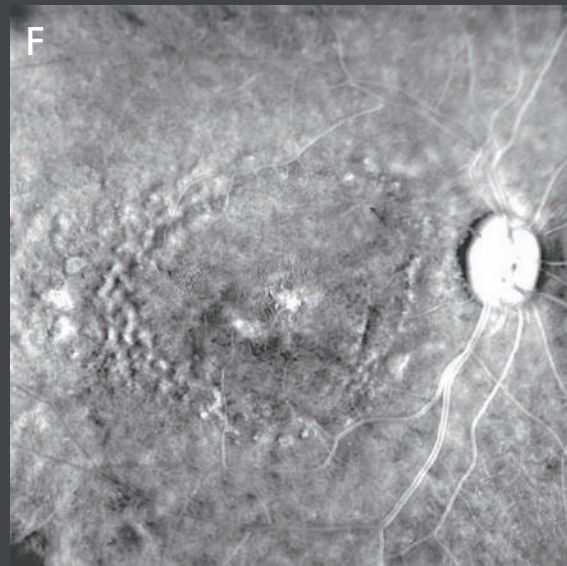
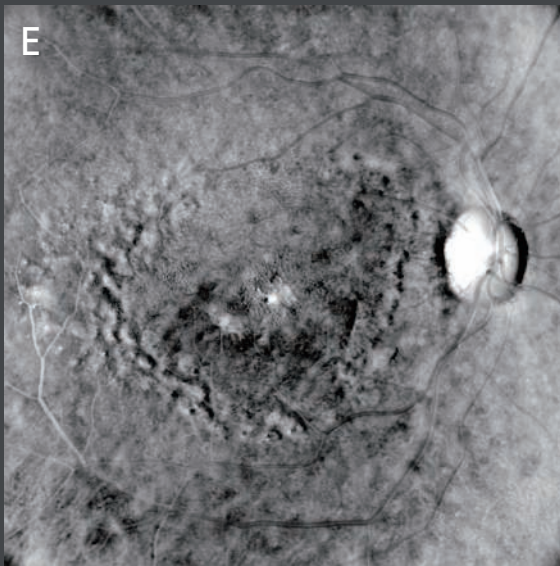
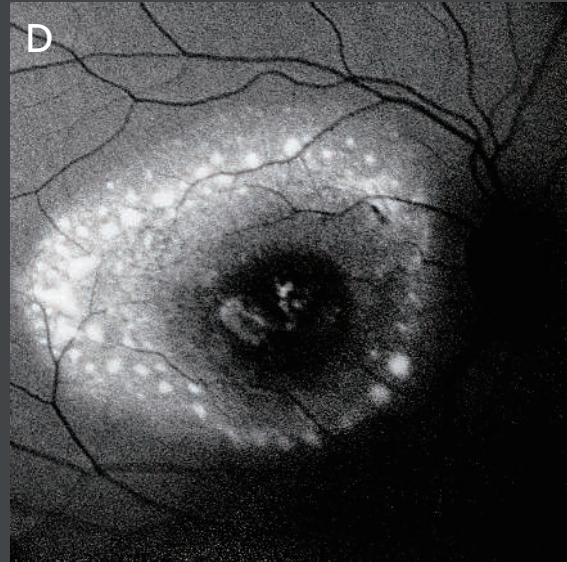
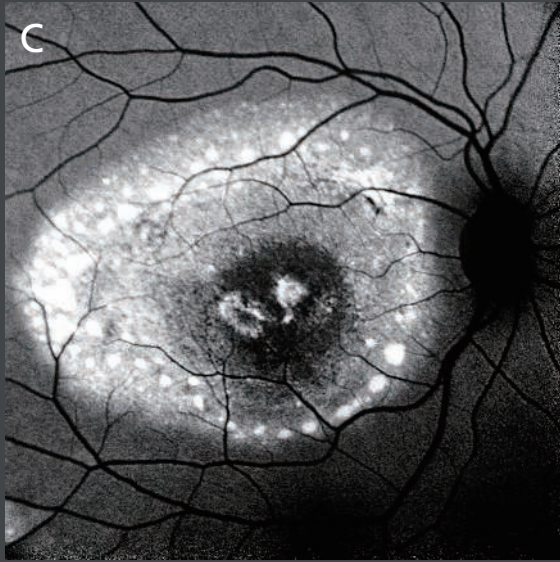


Multimodal imaging of the right eye of a 21-year-old female with Best Vitelliform Macular Dystrophy. Each imaging modality highlights different aspects of the disease.

**[A]** Color confocal imaging shows the accumulation of subretinal yellowish material in the center of the macula with a “scrambled-egg” appearance associated with central fibrosis and a paramacular multi-focal lipofuscin accumulation. Note the color fundus photograph allows different components of the vitelliform lesion and fibrosis to be distinguished based on color.

**[B]** Ultra fine cross-sectional spectral-domain OCT B-scan of the central macula shows elevation of the macula by the hypo-reflective component of the vitelliform lesion with overlying cystoid macular edema reflecting the chronic nature of the degeneration.





Both green [C] and blue [D] fundus autofluorescence are useful in demonstrating the hyper-fluorescent lipofuscin accumulation. The central area of scarring appears hypo-autofluorescent.

[E,F] Retro mode imaging, right-deviated (DR) and left-deviated (DL) clearly delineate the central regions of atrophy, fibrosis, and photoreceptor loss, from the more peripheral accumulations of vitelliform material.



7Ui hcb.1 "G": YXYfU @uk fYgf]VgH ]gXy ]W hc gJYZX]gf]Vi hcbZUbX i gY Vmcf cb hY cfXYf cZUd\ng]V]Ub cf ch Yf "]Wbg/X YnY WfY dfUM]h]cbYF"  
GdYVZM]h]cbga Unj UfmXydYbX]b[ cb V]fW a gUbWg]b YUW Wdi bhfm[GdYVZM]h]cbgUbX XYg] b UfYg VYV]hc WUb[ Y'k ]h ci hbc]hW"



More clinical information available online

<https://www.nidek-intl.com/education/>

