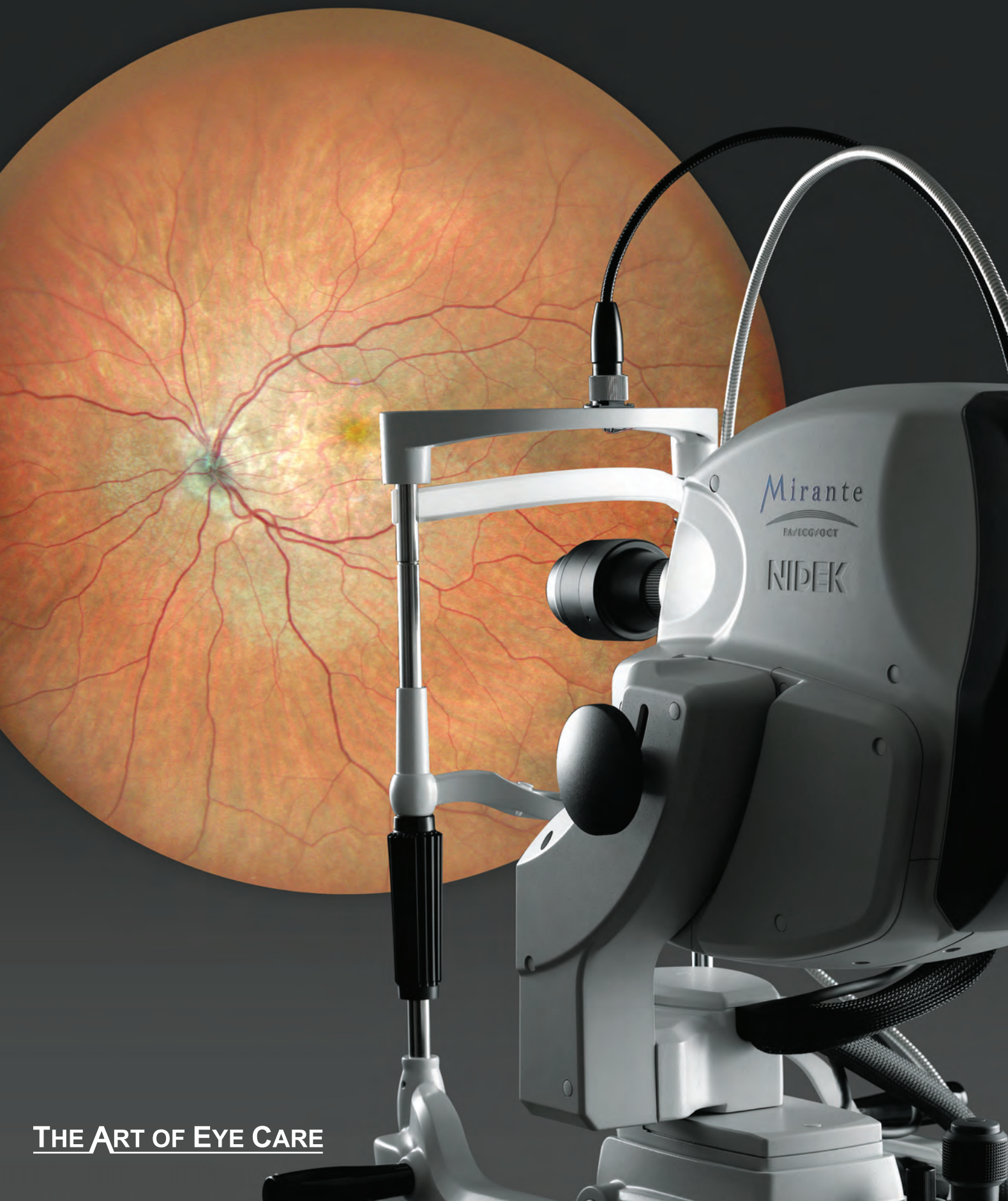




Scanning Laser Ophthalmoscope

Mirante

U.S. EDITION



THE ART OF EYE CARE



The Ultimate Multimodal Imaging Platform

State-of-the-art SLO/OCT Combo

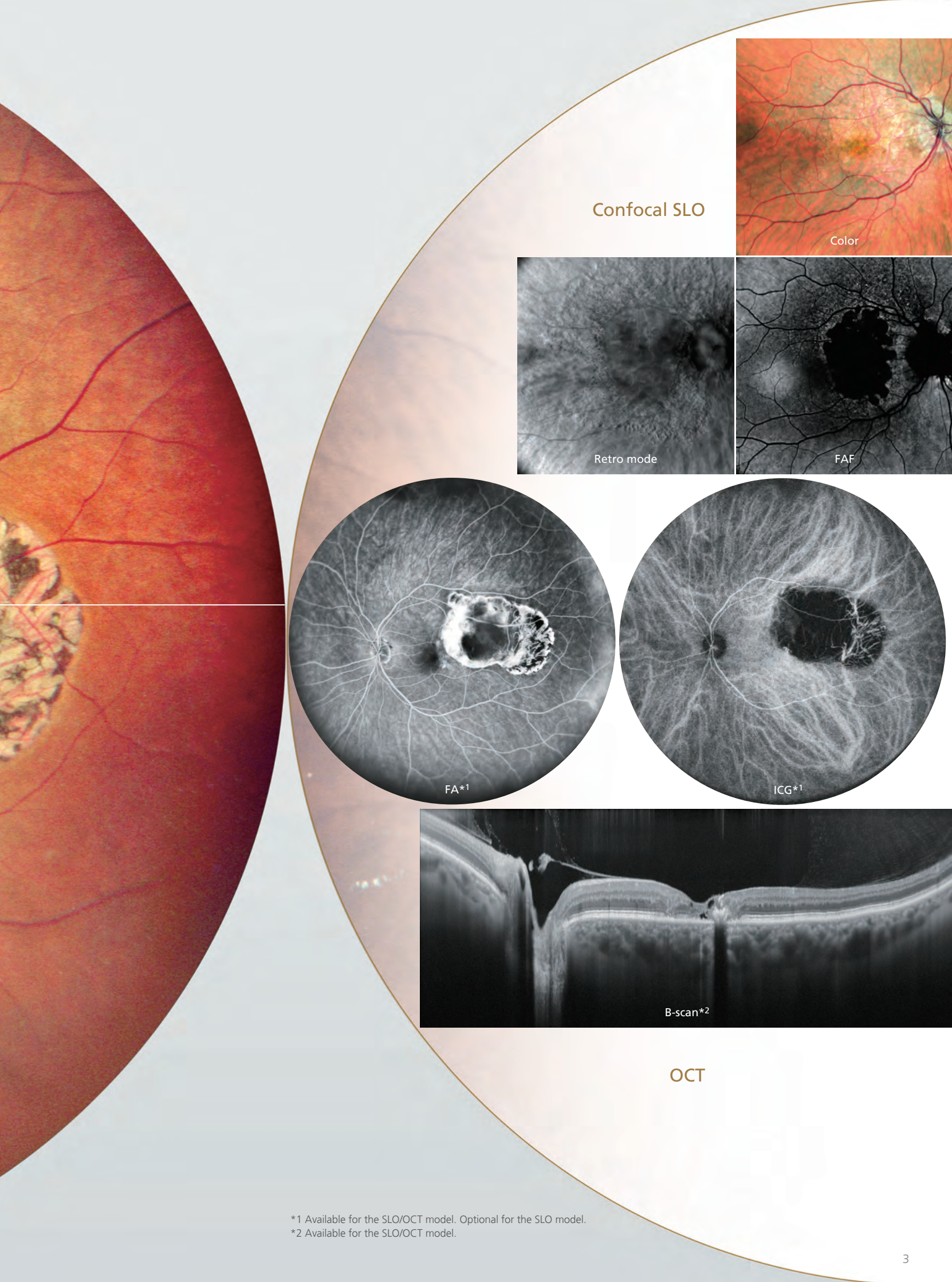
Ultra Wide Field x Ultra HD image

A stellar combination of 163° ultra wide field x ultra 4K HD incorporated in the Mirante achieves a wider, enhanced view of the retinal structure and vasculature with unparalleled clarity.

(Ultra wide field image is available with the included wide-field adapter.)

FlexTrack

The FlexTrack technology improves imaging quality.



Confocal SLO

Color

Retro mode

FAF

FA*1

ICG*1

B-scan*2

OCT

*1 Available for the SLO/OCT model. Optional for the SLO model.

*2 Available for the SLO/OCT model.



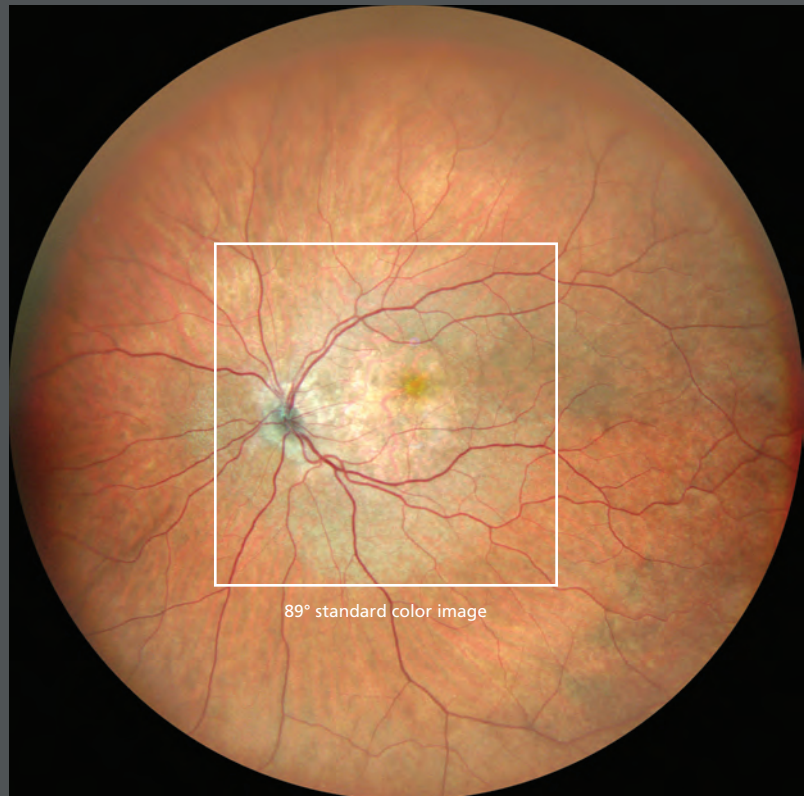
163° ultra wide field color image

The clear image of the entire 163° field of view enables detailed evaluation of pathologies from the fovea to the extreme periphery.

(Ultra wide field imaging is available with the included wide-field adapter.)

Refine mode

As required, capturing two images with slightly different fixation reduces reflection, producing a clear ultra wide field image.

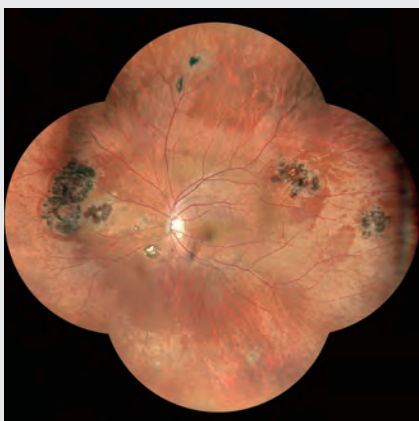


89° standard color image

163° ultra wide field color image

Panorama image composition

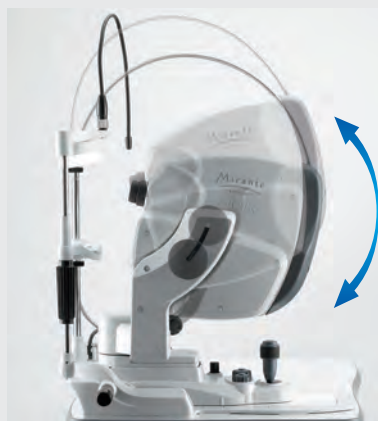Panorama imaging with preset fixation points captures details of pathology even in the extreme periphery.



Panorama image

Tilt and swing features

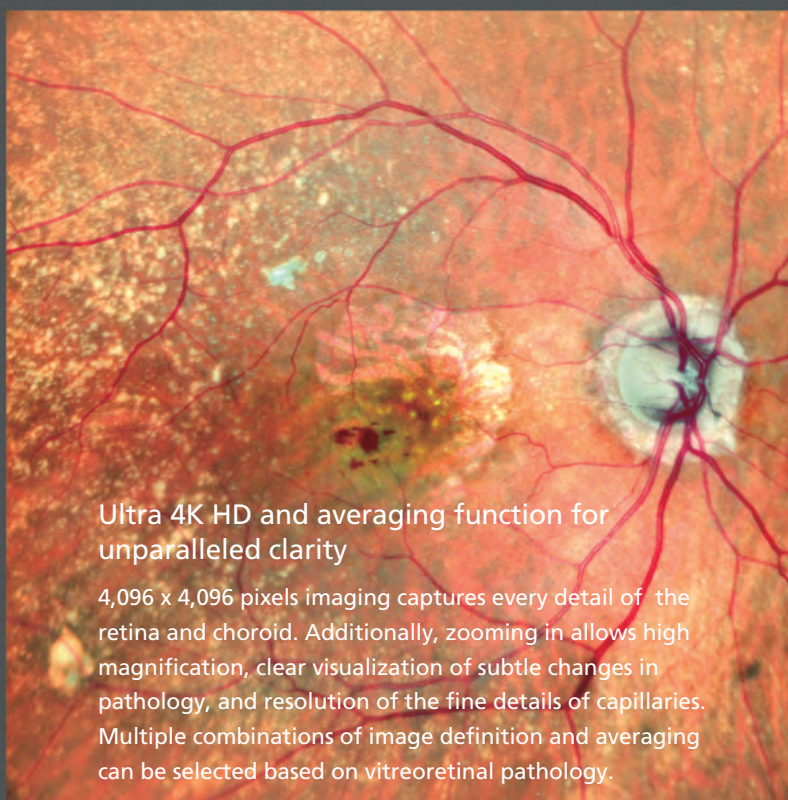
The tilt and swing functions for the optical head allows imaging of the peripheral fundus and acquisition of panorama images. These functions also help for patients with unstable fixation.



Tilt

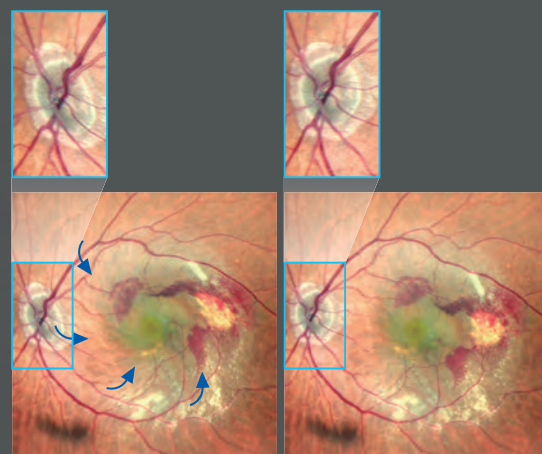


Swing



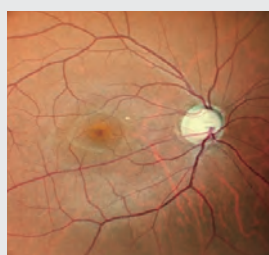
FlexTrack

The FlexTrack algorithm corrects image distortion due to unstable fixation and enhances averaging quality.

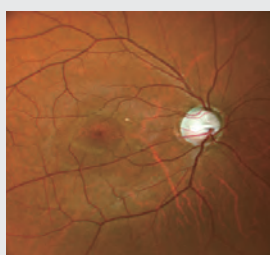


Distorted image due to poor fixation

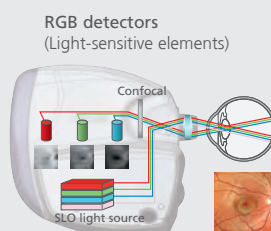
Corrected image using FlexTrack



Color histogram adjusted similar to slit lamp view



Color histogram adjusted similar to fundus camera image

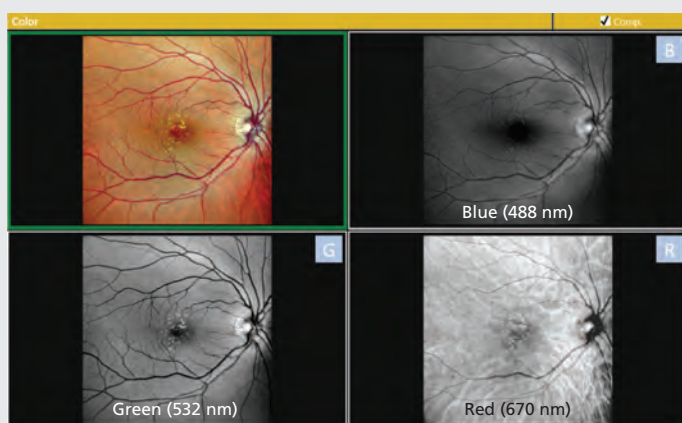


RGB triple detectors

Three separate RGB detectors simultaneously scan different depths of retina with red, green, and blue wavelengths. A color histogram is available for fine adjustment based on pathology or practitioner preference.

RGB color + selectable color display with a single shot

Single color images in red, green, and blue wavelengths can be displayed after color image acquisition. Each wavelength is available with just a single shot, and the image layers can be selected based on user preference or a specific pathology. The viewer software allows image processing options including noise removal and adjustments for brightness, contrast, and sharpness.



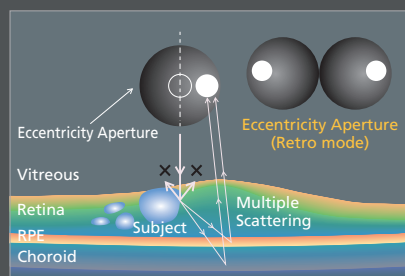
Summary view for RGB color and single color images



Retro mode

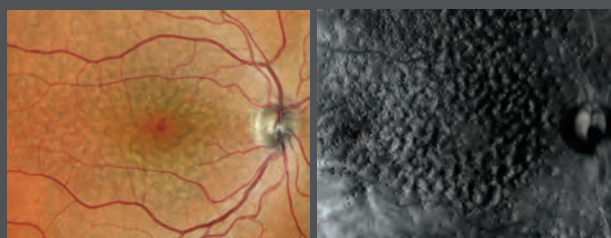Retro mode is a unique non-invasive technique for detecting pathologic changes in the choroid.

This imaging modality uses scattered IR light to detect abnormal reflection in the choroid caused by drusen, edema and other subtle chorioretinal pathologies.



Retro mode

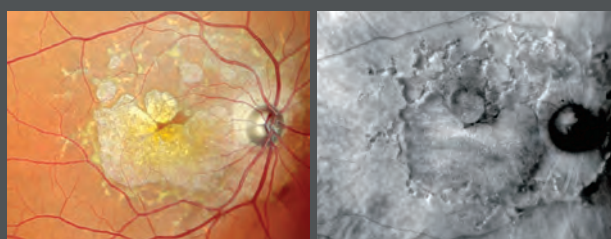
Drusen



Color

Retro mode

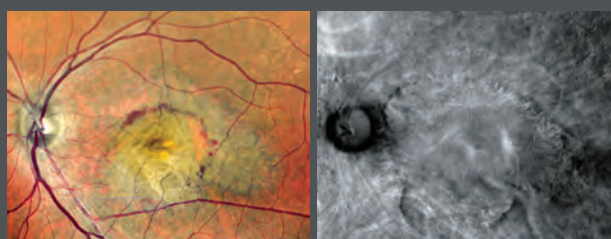
Stargardt disease



Color

Retro mode

CNV



Color

Retro mode

Blue-FAF / Green-FAF (fundus autofluorescence)

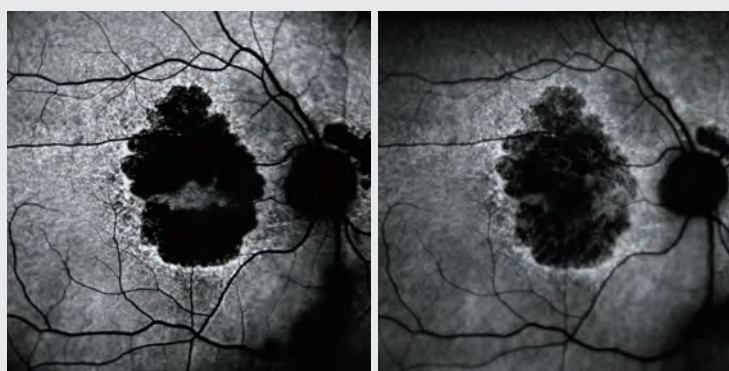
FAF imaging is a non-invasive method to evaluate the retinal pigment epithelium (RPE) without contrast dye.

Green-FAF reduces the effects of xanthophyll from the macula on imaging and is useful for monitoring deeper layers under the macula.

Blue-FAF imaging captures high definition images for diagnosing early AMD.

Gain level and contrast can be adjusted manually or automatically depending on the vitreoretinal pathology.

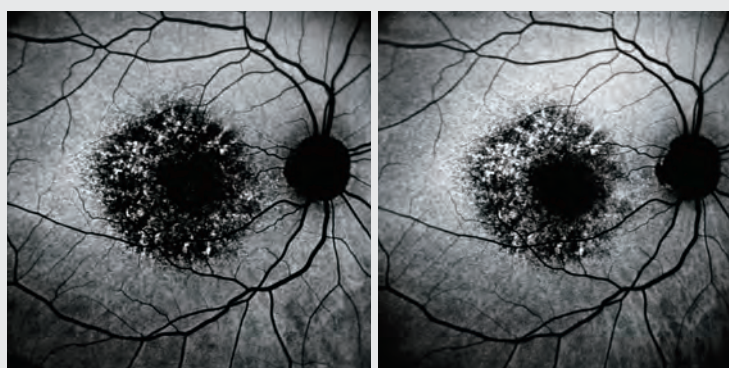
Geographic atrophy



Green-FAF

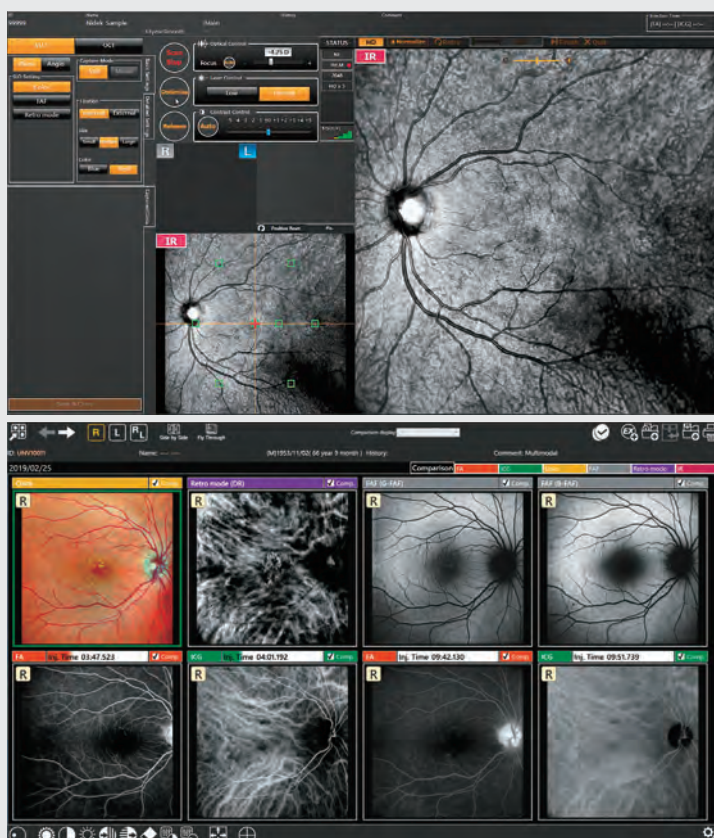Blue-FAF

Macular dystrophy



Green-FAF

Blue-FAF



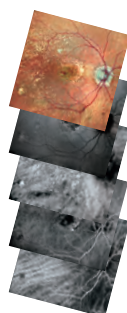
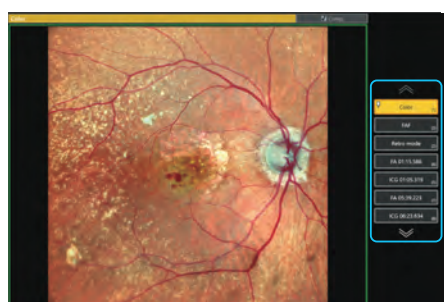
Simple interface and easy operation

The Mirante has multiple modalities and functions with interface software that presents these choices in a simple, easy-to-use manner. Image acquisition with the Mirante is simple. The SLO image is focused automatically by pressing the optimize button. After optimization is completed, the image can be captured by pressing the release button.

Presenting multimodal images in a summary screen allows faster, more comprehensive evaluation of disease.

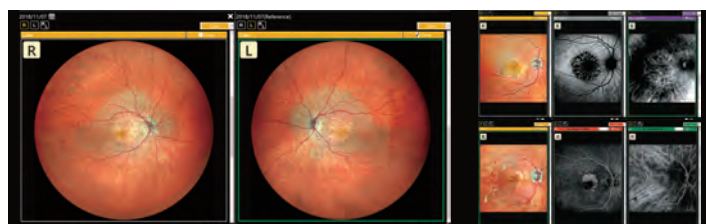
Streamlined combination capture

The Combo image capture allows sequential capture of images with the preset combination of image capture settings for each specified disease.



Fly Through

The Fly Through function further enhances multimodal imaging by registering and synchronizing images from different modalities to view the same area while scrolling through the region of interest.



Side by Side

The Side by Side function displays up to 3 images on one screen for all SLO modalities for the left and right eyes and displays the images in chronological order.

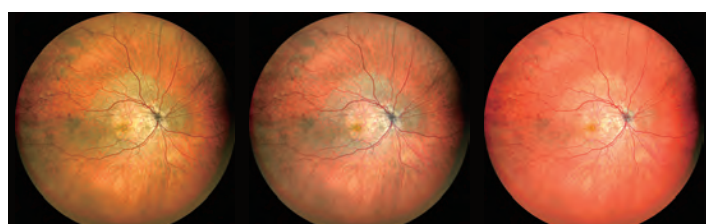

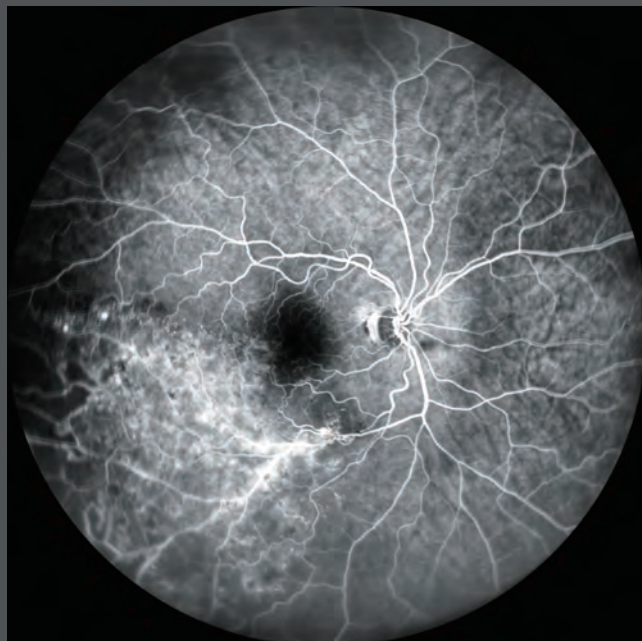Image processing preset

Image processing parameter settings allow the clinician to easily display images in the preferred retinal color.

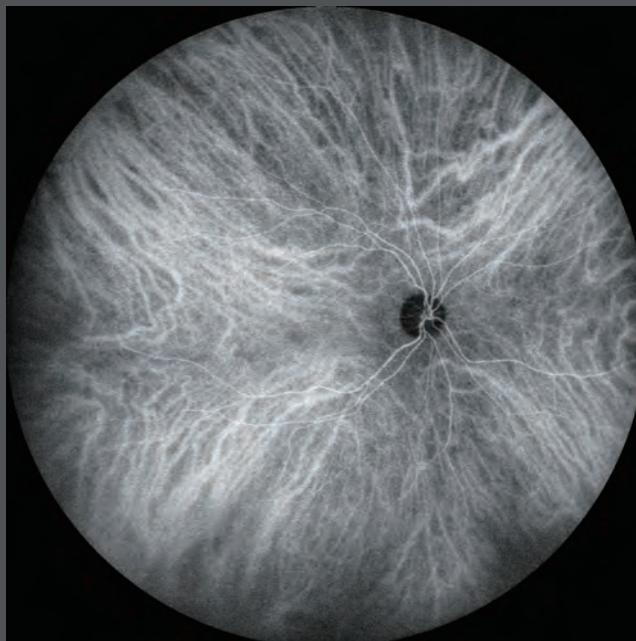


163° ultra wide field FA and ICG images

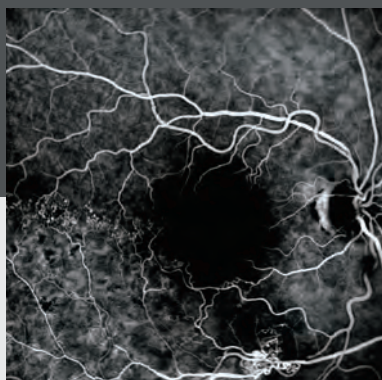
(Ultra wide field imaging is available with the included wide-field adapter.)



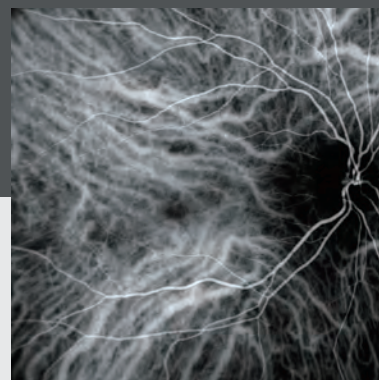
163° ultra wide field FA image



163° ultra wide field ICG image



89° standard FA image



89° standard ICG image

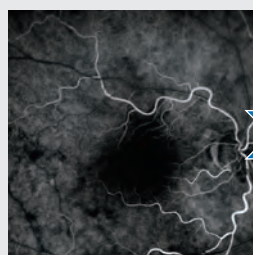HD dynamic and static angiogram

Auto gain control (AGC) optimizes gain levels and contrast for early, peak, and late phase angiography.

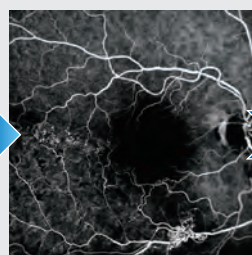
High definition imaging up to 16 megapixels, can be selected based on ocular pathology. The averaging function for static and dynamic imaging ensures high contrast even during late phase angiography while simultaneously reducing noise on images and video.

Videos can be recorded at a maximum of 1,024 x 1,024 pixels for up to 120 seconds. Multiple short videos can be recorded during the same measurement.

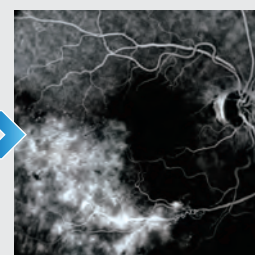
FA



Early phase

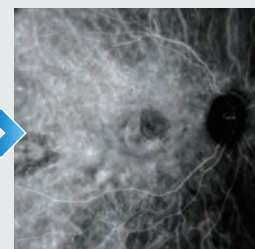
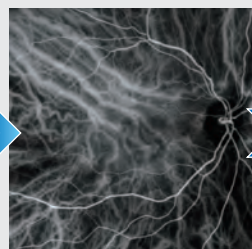
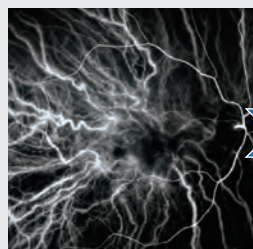


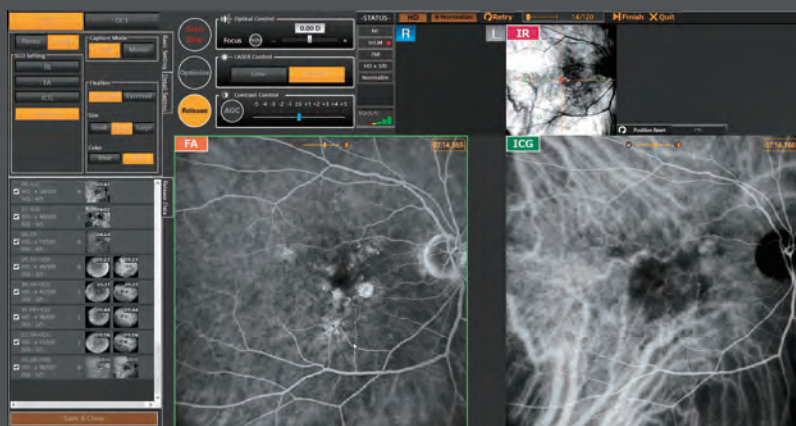
Mid phase



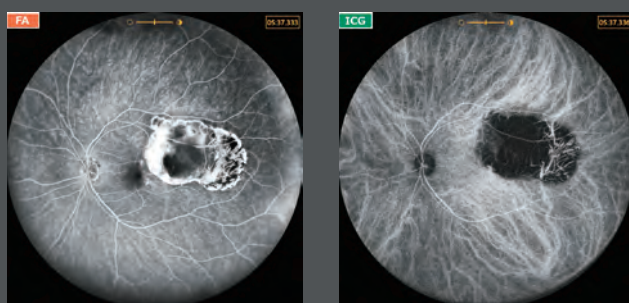
Late phase

ICG





Simultaneous FA and ICG imaging display (standard)

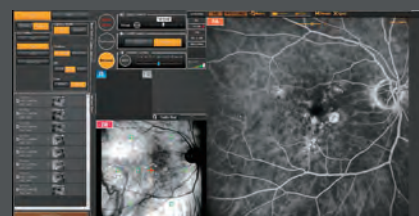

Simultaneous FA and ICG imaging display (ultra wide field)

Simultaneous FA and ICG

The Mirante allows simple, simultaneous acquisition of FA and ICG images. The live IR monitoring enables alignment prior to fluorescence emission and reduces the risk of missing the very early phase of angiography.

The AGC simultaneously adjusts contrast of each FA and ICG image, making the imaging of dynamic blood flow a very simple procedure.

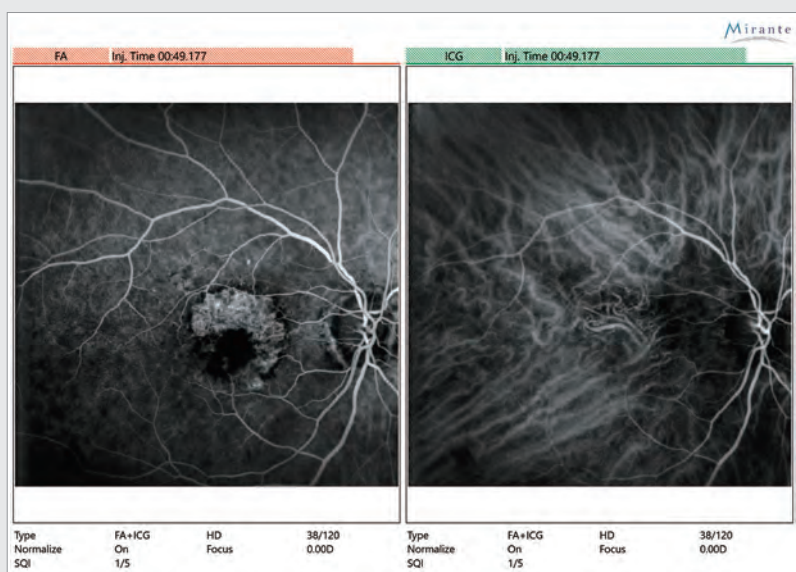


Live IR monitoring

Using live IR monitoring, physicians can start alignment before fluorescence emission.

Easy comparison of FA and ICG

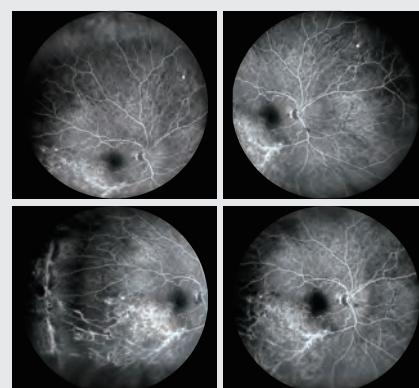
The viewer software can present FA and ICG images side-by-side, facilitating convenient and comprehensive evaluation of angiography.



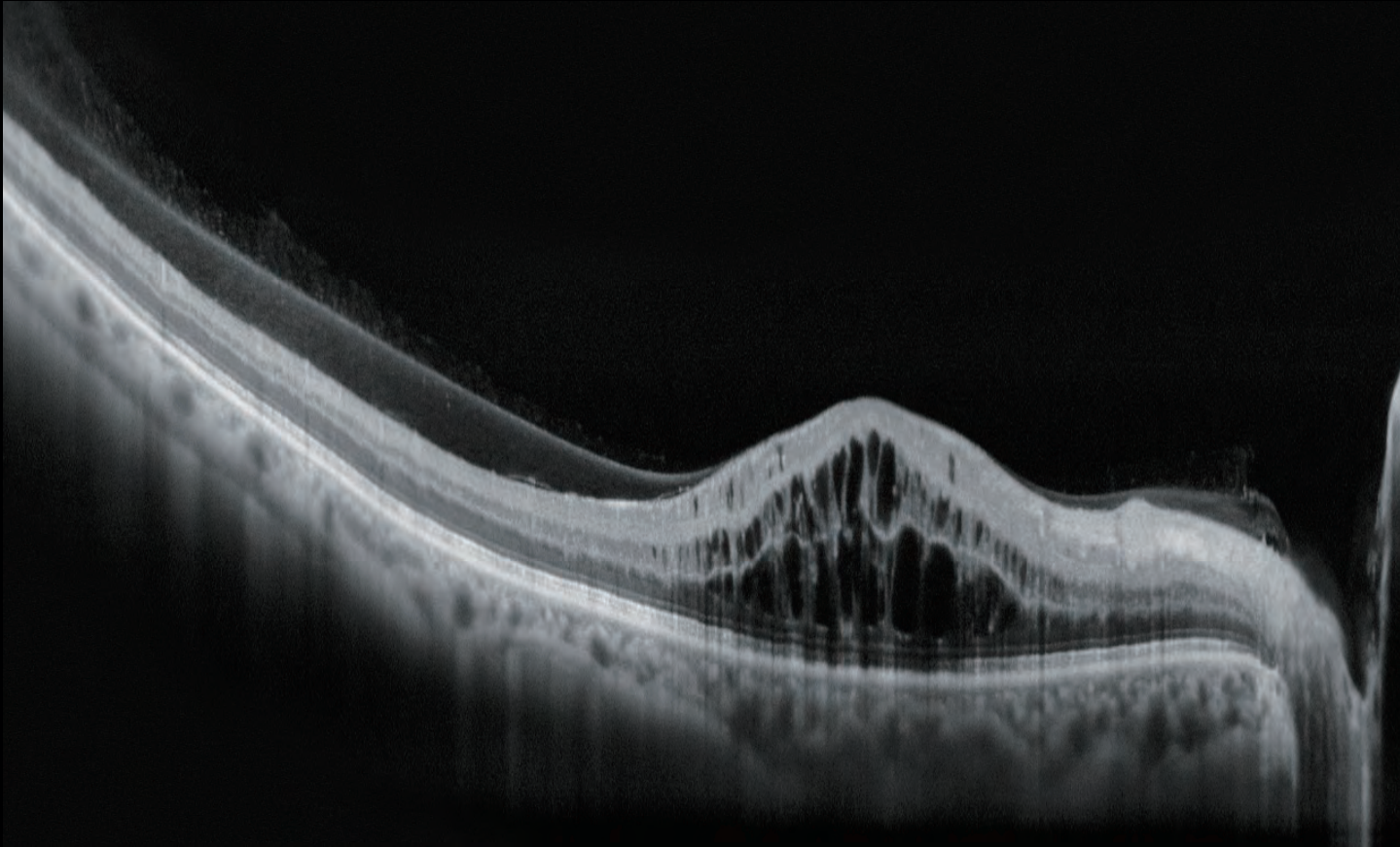
Side-by-side display of FA and ICG

FA and peripheral fundus

The tilt and swing features and ultra wide field capability allows peripheral imaging during fluorescein angiography.



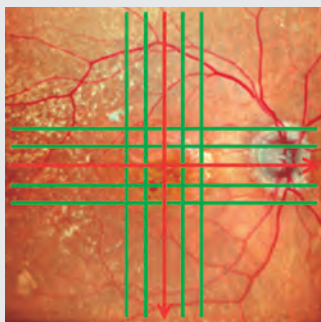
FA of the peripheral fundus



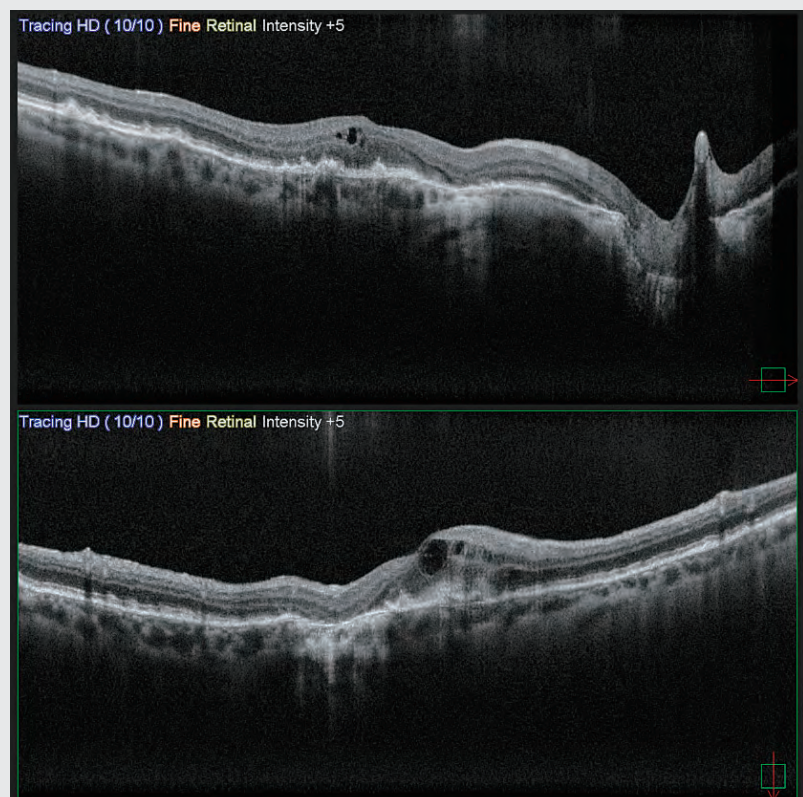Macula line 16.5 mm / 2,048 A-scans

HD wide area OCT

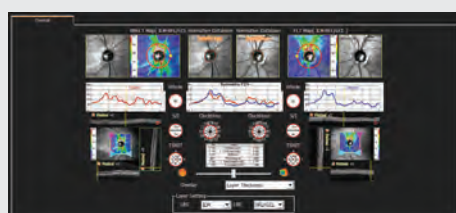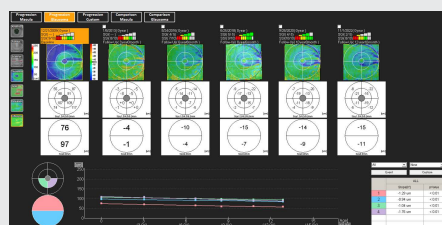
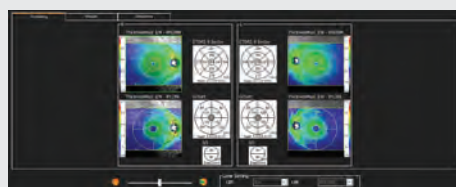
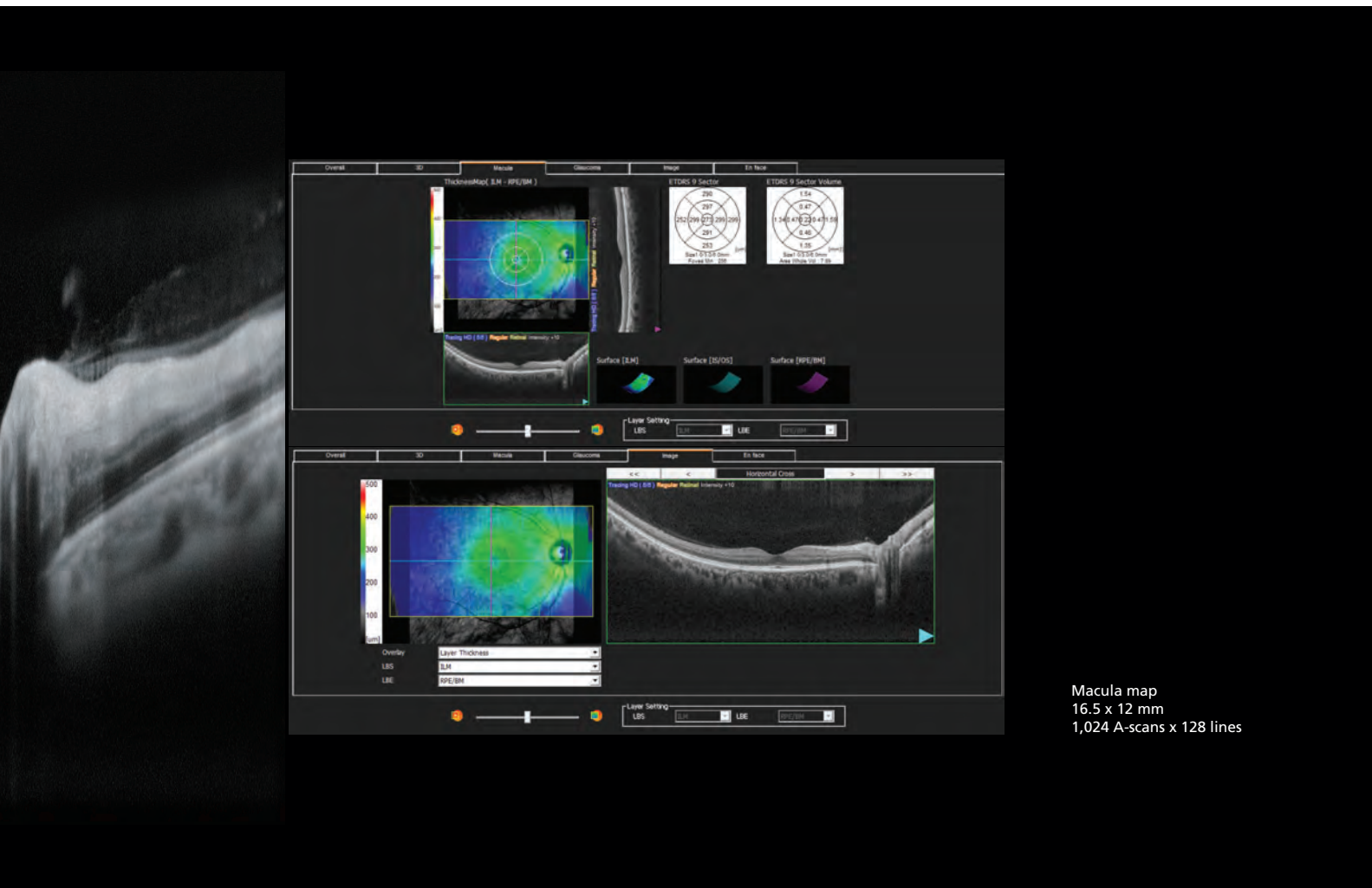
The maximum 16.5 x 12 mm area scan available with the Mirante allows wide area diagnosis including the macula and optic disc in a single shot. The ultra fine mode and tracing HD plus functions provide high quality images for detailed observation from the vitreous layers to the choroid.



SLO image



Macula multi cross 12 x 12 mm



Glaucoma analysis

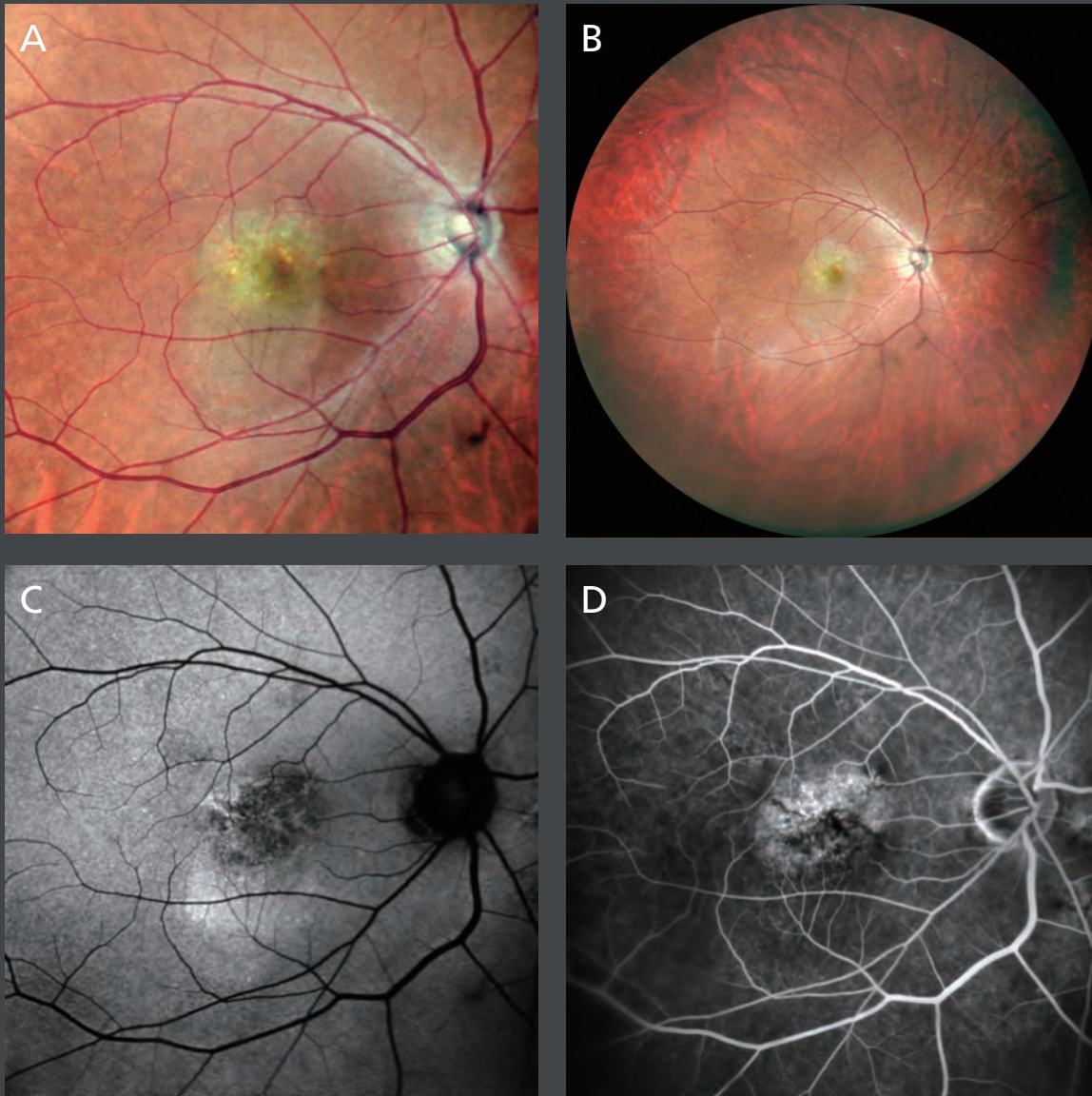
The Mirante incorporates 16.5 x 12 mm thickness map which visually presents pathological changes from the central retina to the periphery.

9 x 9 mm allows [NFL+GCL+IPL] analysis from optic disc to macula in a single report.

Case:

Choroidal Neovascularization Associated with Age-related Macular Degeneration (AMD) with Central Serous Chorioretinopathy (CSCR)

Authors: Giulia Corradetti, MD, Srinivas Sadda, MD, Doheny Eye Institute, UCLA, USA

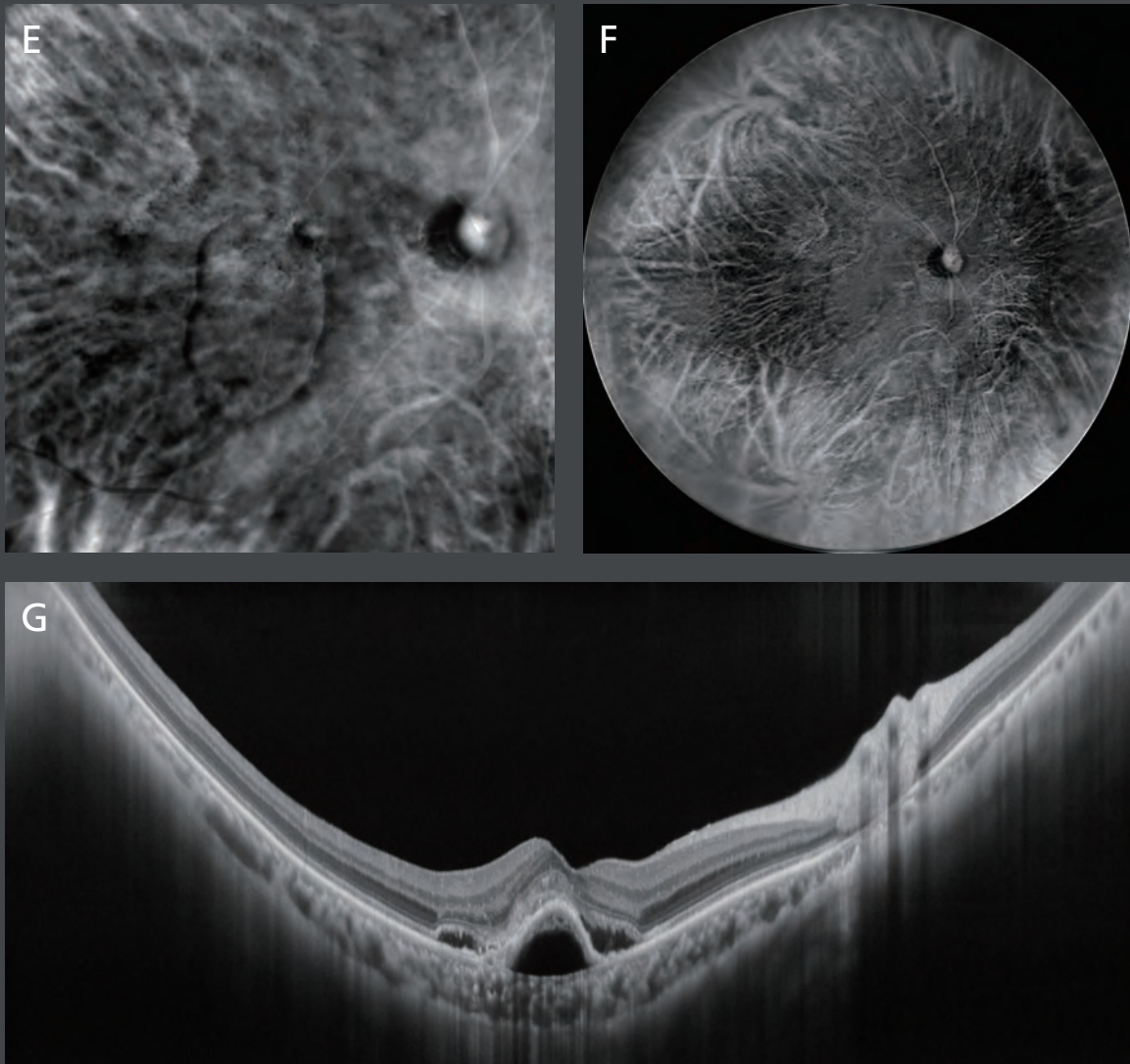


Multimodal imaging of a case of choroidal neovascularization associated with AMD with some CSCR-like features in an 85-year-old male.

[A,B] Standard and ultra wide field color fundus photographs captured with the Mirante confocal scanning laser ophthalmoscopy are presented using three different channels (blue, green, and red) with central angles of 89° and 163°, respectively. Both images show a smooth and well-circumscribed yellowish fibrovascular pigment epithelial detachment (PED) involving the central macula.

[C] Green autofluorescence shows a central area of mottled hypo-autofluorescence highlighting the altered retinal pigment epithelium in the region of the PED, with adjacent hyper-autofluorescence inferiorly corresponding to the subretinal fluid.

[D] Early phase fluorescein angiography shows irregular, stippled hyper-fluorescence corresponding to the fibrovascular PED.



[E,F] Retro mode left-deviated (DL), standard and ultra wide field images, respectively, show a vertical oval-shaped slightly hyper-reflective region with a rim of hypo-reflectivity corresponding to the neurosensory detachment. The vertically-oblong shape suggests the gravitational nature of the fluid distribution. The Retro mode technology, using an eccentric confocal aperture, provides additional contrast to display the fluid and its extent.

[G] An ultra fine cross-sectional spectral-domain OCT image through the foveal center (120X averaged) demonstrates a fibrovascular PED with a secondary elevation of the overlying retina and subretinal fluid. Note, the internal characteristics of the PED are visible, with fibrovascular tissue at the apex of the PED and subretinal pigment epithelium fluid at the base. The full extent of the choroid is visualized and appears to be thick given the patient's age.

Wide-field adapter (Included)

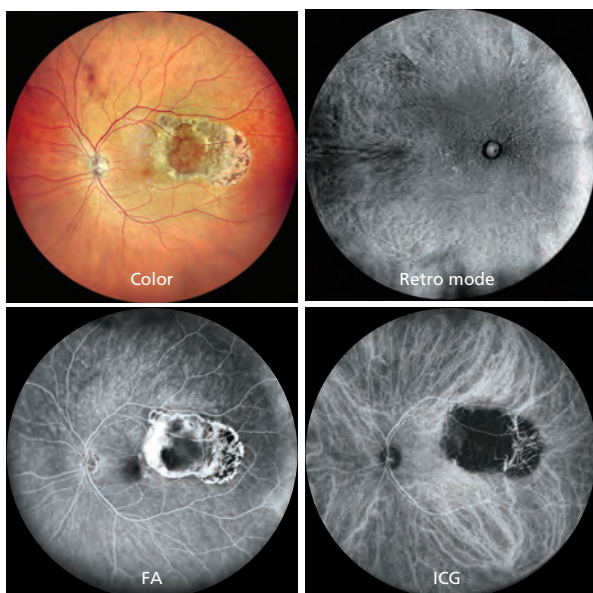
163° ultra wide field imaging is available with the included wide-field adapter.



Anterior segment OCT adapter* (Optional)

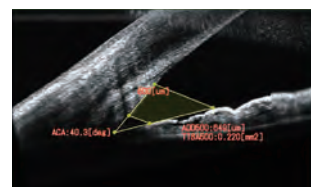
The optional anterior segment module enables observation and analyses of the anterior segment.

* Available for the SLO/OCT model.




<Angle measurement>

- ACA
- AOD500 (AOD750)
- TISA500 (TISA750)

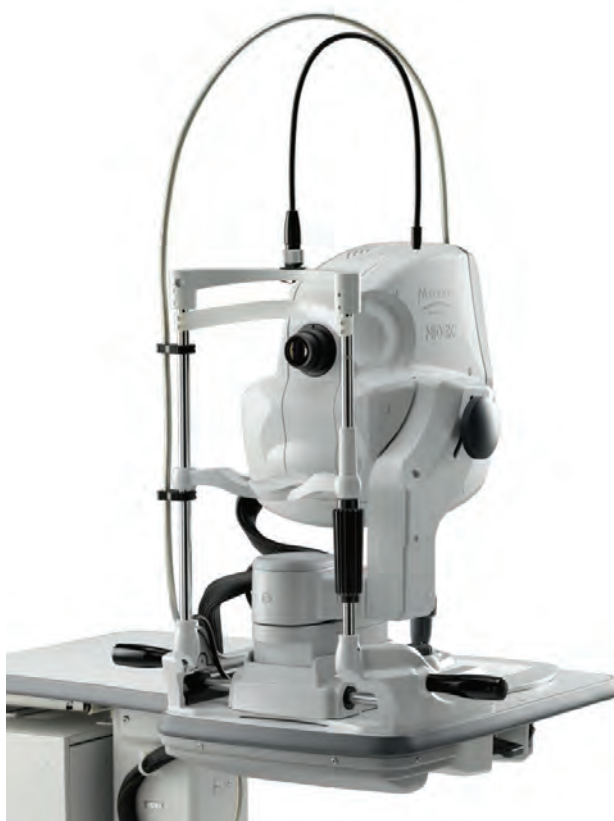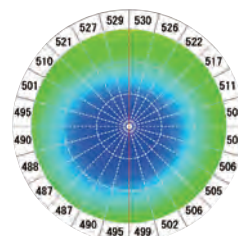


<Cornea measurement>

- Corneal thickness
Corneal apical thickness and user designated locations



- Corneal thickness map
Map indicating corneal thickness plotted radially



Function overview - Mirante and RS Series

●: Available

				Mirante SLO/OCT	Mirante SLO	RS-3000 Advance
SLO/ Fundus image	Angle of view	Ultra wide field*1	163°*2	●	●	
		Standard	89°*2	●	●	
	Still image definition (pixel x pixel)	4,096 x 4,096		●	●	
		2,048 x 2,048		●	●	
		1,536 x 1,536		●	●	
		1,024 x 1,024		●	●	
		768 x 768		●	●	
		512 x 512		●	●	
	Color fundus	Color		●	●	
	Fundus fluorescence	FA/ICG		●	● *4	
	Fundus autofluorescence	Blue-FAF		●	●	
		Green-FAF		●	●	
	Retro mode	DR/DL/RA		●	●	
	Red-free	RGB		●	●	
OCT	Scan speed	Up to 85,000 A-scans/s		●		
		Up to 53,000 A-scans/s				●
	OCT sensitivity	Regular	85,000 A-scans/s	●		
			53,000 A-scans/s			●
		Fine	53,000 A-scans/s	●		
			26,500 A-scans/s			●
		Ultra fine	13,250 A-scans/s	●		●
	A-scan	2,048 points		●		
		1,024 points		●		●
		512 points		●		●
		256 points		●		●
	B-scan*3	256 scans		●		●
		128 scans		●		●
		64 scans		●		●
		32 scans		●		●
		16 scans		●		●
	Scan range	X: 3 to 16.5 mm		●		
		X: 3 to 12 mm				●
		Y: 3 to 13.2 mm		●		
		Y: 3 to 9 mm				●
	Scan wavelength	880 nm		●		●

*1 Ultra wide field imaging is available with the included wide-field adapter.

*2 Measured from the center of the eye

*3 Only for macula map and disc map

*4 Optional

Mirante Specifications

SLO	
Principal	Confocal scanning
Angle of view	Standard: Diagonal angle of view 89°
(Measured from the center of the eye)	Ultra wide field*1: ø163°
Light source	488, 532, 670, 790 nm
Still image size	4,096 x 4,096, 2,048 x 2,048, 1,536 x 1,536, 1,024 x 1,024, 768 x 768, 512 x 512 (pixel x pixel)
Video size*2	1,024 x 1,024, 768 x 768, 512 x 512 (pixel x pixel)
Minimum pupil diameter	ø3.3 mm
Working distance	Standard: 19 mm / Ultra wide field*1: 9 mm
OCT*3	
Principal	Spectral domain OCT
Optical resolution	Z: 7 µm, X-Y: 20 µm
Scan range	
Retina	X: 3 to 16.5 mm, Y: 3 to 13.2 mm, Z: 2.1 mm
Anterior*4	X: 2 to 8 mm, Z: 2.1 mm
OCT light source	SLD, 880 nm
Scan speed	Up to 85,000 A-scans/s
Image averaging	Up to 120 images
	9 x 9 mm (macula), 6 x 6 mm (disc)
Minimum pupil diameter	ø2.5 mm
Working distance	Standard: 19 mm / Anterior*4: 15.4 mm
Software analysis	
Retina	Segmentation of 6+1 retinal layers, macular thickness map, RNFL thickness map, [NFL+GCL+IPL] analysis, optic nerve analysis
Anterior*4	Corneal thickness measurement, corneal thickness map, angle measurement
Common specification	
Diopter correction range	-15 to +15 D
Internal fixation lamp	Red (670 nm) / blue (488 nm)
External fixation lamp	White
Tilt	±10°
Swing	±20°
PC networking	Available
Power supply	100 to 240 V AC, 50/60 Hz
Power consumption	Device main body 150 VA
Dimensions/mass*5	345 (W) x 548 (D) x 527 to 557 (H) mm / 23 kg (SLO/OCT model) 22 kg (SLO model) 13.6 (W) x 21.6 (D) x 20.7 to 21.9 (H) " / 51 lbs. (SLO/OCT model) 49 lbs. (SLO model)
Optional accessories	Wide-field adapter, motorized optical table, PC rack, isolation transformer, external fixation lamp (multi-joint), anterior segment OCT adapter*3, B-Scan Denoising Software*3, FA/ICG dongle*6, FA dongle*6

*1 Ultra wide field imaging is available with the included wide-field adapter.

*2 Optional for the SLO model.

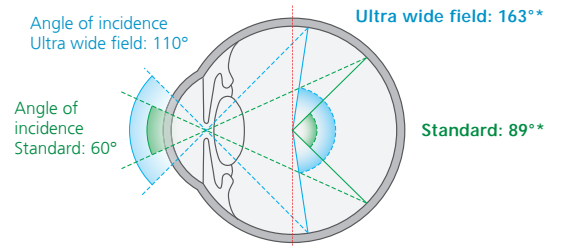
*3 Available for the SLO/OCT model.

*4 Anterior segment OCT adapter is optional.

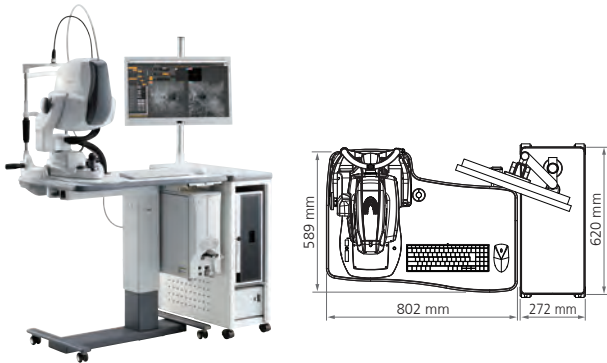
*5 Only for image capturing unit.

*6 Available for the SLO model.

Central angle of view



* Measured from the center of the eye



Images courtesy of
Luigi Sacco Hospital, University of Milan, Italy
Asia Eye Centre, Singapore
Doheny Eye Center, UCLA, USA
Retina Foundation & Eye Research Center, India
Kagoshima University Hospital, Japan
Exilaser Clinic, Peru
Chiba University Hospital, Japan
Tohoku University, Japan
Careggi University Hospital, University of Florence, Italy



More clinical information available
online at the NIDEK Education page

For more clinical information, please visit the
Education page on the NIDEK website. This site
allows access to case reports, journal articles,
and video presentations.



<https://www.nidek-intl.com/education/>

Caution: U.S. Federal Law restricts this device to sale, distribution, and use by or on the order of a physician or other licensed eye care practitioner.
Specifications may vary depending on circumstances in each country. Specifications and design are subject to change without notice.



NIDEK INC.
2040 Corporate Court,
San Jose, CA 95131, U.S.A.
TEL: +1-408-468-6400
+1-800-223-9044
(US Only)
URL: usa.nidek.com

TOKYO OFFICE
(International Div.)
3F Sumitomo Fudosan Hongo
Bldg., 3-22-5 Hongo, Bunkyo-ku,
Tokyo 113-0033, JAPAN
TEL: +81-3-5844-2641
URL: www.nidek.com

HEAD OFFICE
(International Div.)
34-14 Maehama,
Hiroishi-cho, Gamagori,
Aichi 443-0038, JAPAN
TEL: +81-533-67-8895
URL: www.nidek.com
[Manufacturer]

NIDEK S.A.
Ecoparc,
9 rue Benjamin Franklin,
94370 Sucy En Brie,
FRANCE
TEL: +33-1-49 80 97 97
URL: www.nidek.fr

NIDEK TECHNOLOGIES S.R.L.
Via dell'Artigianato,
6/A, 35020 Albignasego (Padova),
ITALY
TEL: +39 049 8629200/8626399
URL: www.nidektechnologies.it

NIDEK (SHANGHAI) CO., LTD.
Rm3205, Shanghai Multi
Media Park, No.1027 Chang
Ning Rd, Chang Ning District,
Shanghai, CHINA 200050
TEL: +86 021-5212-7942
URL: www.nidek-china.cn

NIDEK SINGAPORE PTE. LTD.
51 Changi Business Park
Central 2, #06-14,
The Signature 486066,
SINGAPORE
TEL: +65 6588 0389
URL: www.nidek.sg