

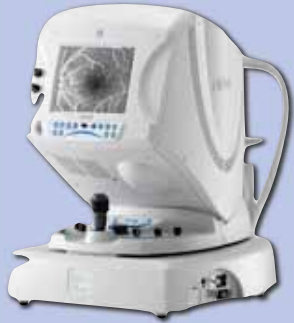Comparison between Retro-mode and “OCT map” in Macular Edema detection

Claudia Orini¹, Paola Salvetti¹, Alberto Pazzaglia², Lisa Toto³, Maurizio Battaglia Parodi⁴, Francesco Bandello⁴, Giovanni Staurenghi¹.

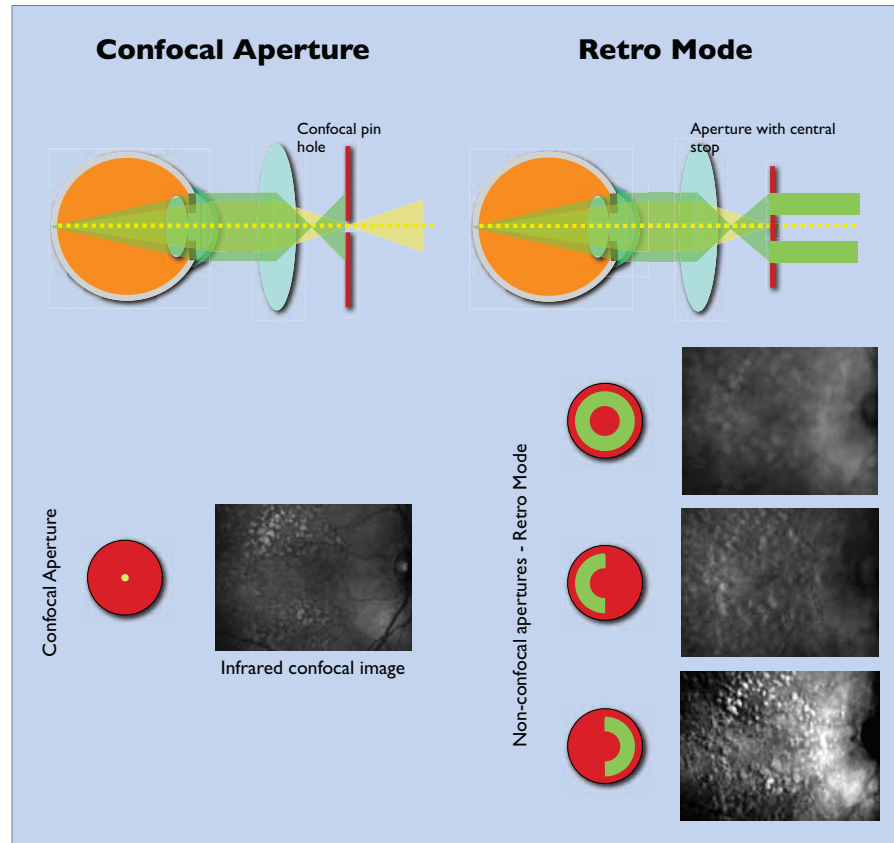
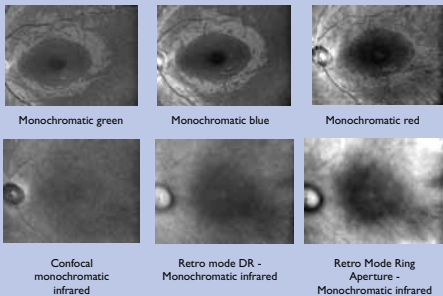
¹ Ophthalmologic Clinic, Clinic Sciences Department “Luigi Sacco” University of Milan -- ² University of Bologna, ³ Ophthalmologic Clinic, Gabriele D’Annunzio University of Chieti-Pescara, ⁴ University of Udine

Aim:
Comparing the retro mode images obtained with the Nidek F-10 angiograph and the retinal thickness maps obtained with Zeiss Cirrus OCT.

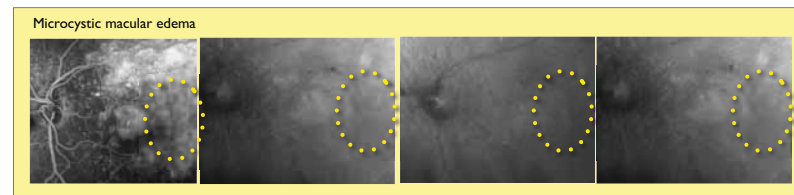

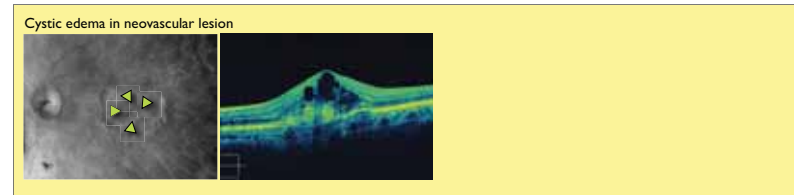
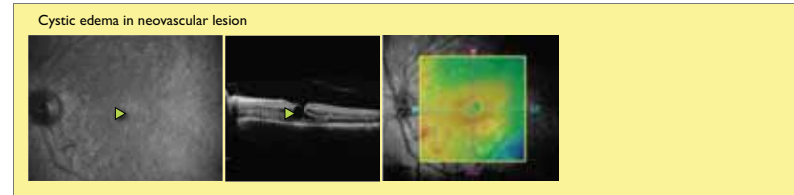
Methods and Patients:
57 patients affected by macular edema (diagnosed by FAG), recruited in the ophthalmologic clinics of Bologna, Udine, Chieti and Milan-Sacco Hospital, have been visited with the Nidek F-10 angiograph in retro mode configuration and the obtained images have been compared with the retinal thickness Cirrus OCT maps by two independent observers (CO, PS).
The sensitivity, the specificity and the predictive negative and positive value of the test have been evaluated



Nidek F-10 is a new scanning laser angiograph that allows to observe the retinal fundus with 4 different laser wavelengths: blue, green, red and infrared.



Visualization examples of retinal edema in various pathologies



Results:

- Sensitivity: 96% very good ability to detect the presence of a macular edema
- Specificity: 31 % the Nidek F-10 can detect the edemas not detected by OCT.
- VPP: 57% probability that a retro mode edema diagnosis corresponds to a real edema pathology
- VPN: 90% probability that a negative retro mode diagnosis corresponds to a missing edema situation.

Conclusions
The Retro mode imaging technique can be considered useful to evaluate, in a non-invasive way, the retinal macular edema.