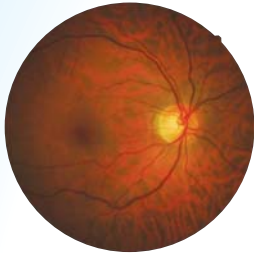
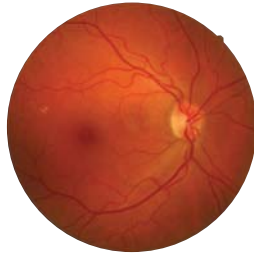
The Art of Eye Care

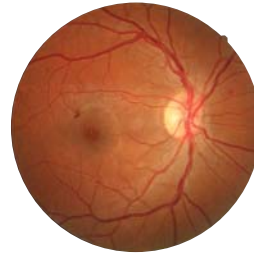Diabetic Eye Disease



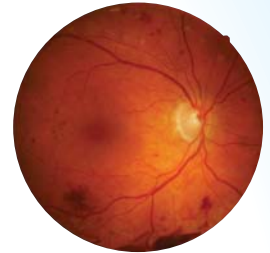Normal



Early

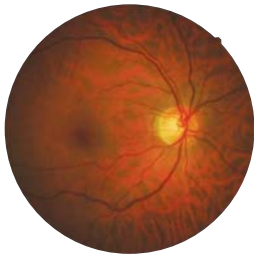

Nonproliferative

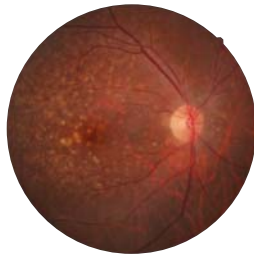

Proliferative

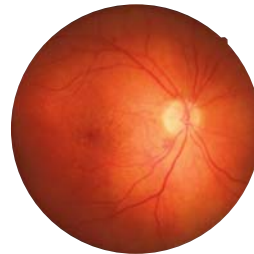
Macular Degeneration



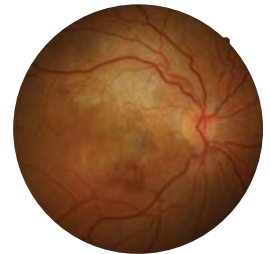Normal



Dry

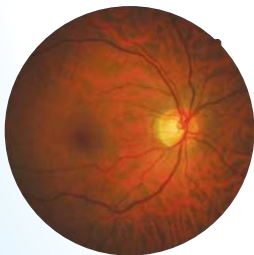

Wet

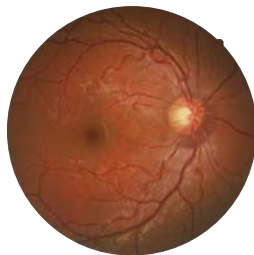


Severe Wet

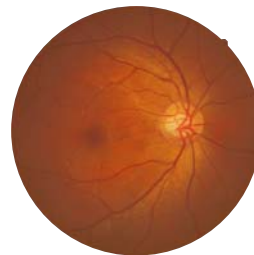
Glaucoma



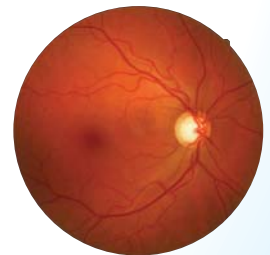
Normal



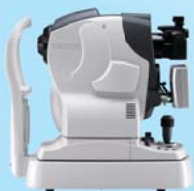Mild



Moderate



Severe



AFC
Pro Photographer
Digital Imaging

